

Journal of Feline Medicine and Surgery

<http://jfm.sagepub.com/>

Ultrasonographic thickening of the muscularis propria in feline small intestinal small cell T-cell lymphoma and inflammatory bowel disease

Lise A Daniaux, Michele P Laurenson, Stanley L Marks, Peter F Moore, Sandra L Taylor, Rachel X Chen and Allison L Zwingenberger

Journal of Feline Medicine and Surgery 2014 16: 89 originally published online 30 July 2013

DOI: 10.1177/1098612X13498596

The online version of this article can be found at:

<http://jfm.sagepub.com/content/16/2/89>

Disclaimer

The Journal of Feline Medicine and Surgery is an international journal and authors may discuss products and formulations that are not available or licensed in the individual reader's own country. Furthermore, drugs may be mentioned that are licensed for human use, and not for veterinary use. Readers need to bear this in mind and be aware of the prescribing laws pertaining to their own country. Likewise, in relation to advertising material, it is the responsibility of the reader to check that the product is authorised for use in their own country. The authors, editors, owners and publishers do not accept any responsibility for any loss or damage arising from actions or decisions based on information contained in this publication; ultimate responsibility for the treatment of animals and interpretation of published materials lies with the veterinary practitioner. The opinions expressed are those of the authors and the inclusion in this publication of material relating to a particular product, method or technique does not amount to an endorsement of its value or quality, or the claims made by its manufacturer.

Published by:

[International Society of Feline Medicine](#)



[American Association of Feline Practitioners](#)



and

<http://www.sagepublications.com>

Additional services and information for *Journal of Feline Medicine and Surgery* can be found at:

Email Alerts: <http://jfm.sagepub.com/cgi/alerts>

Subscriptions: <http://jfm.sagepub.com/subscriptions>

Reprints: <http://www.sagepub.com/journalsReprints.nav>

Permissions: <http://www.sagepub.com/journalsPermissions.nav>

>> [Version of Record](#) - Jan 20, 2014

[OnlineFirst Version of Record](#) - Jul 30, 2013

Downloaded from jfm.sagepub.com at Univ of Connecticut Health Center Library on June 22, 2014

What is This?



Ultrasonographic thickening of the muscularis propria in feline small intestinal small cell T-cell lymphoma and inflammatory bowel disease

Journal of Feline Medicine and Surgery
 2014, Vol 16(2) 89–98
 © ISFM and AAEP 2013
 Reprints and permissions:
sagepub.co.uk/journalsPermissions.nav
 DOI: 10.1177/1098612X13498596
jfms.com


Lise A Daniaux¹, Michele P Laurenson¹, Stanley L Marks²,
 Peter F Moore³, Sandra L Taylor⁴, Rachel X Chen⁴ and
 Allison L Zwingenberger⁵

Abstract

Gastrointestinal lymphoma is the most common form of lymphoma in the cat. More recently, an ultrasonographic pattern associated with feline small cell T-cell gastrointestinal lymphoma has been recognized as a diffuse thickening of the muscularis propria of the small intestine. This pattern is also described with feline inflammatory bowel disease. To evaluate the similarities between the diseases, we quantified the thickness of the muscularis propria layer in the duodenum, jejunum and ileum of 14 cats affected by small cell T-cell lymphoma and inflammatory bowel disease (IBD) and 19 healthy cats. We found a significantly increased thickness of the muscularis propria in cats with lymphoma and IBD compared with healthy cats. The mean thickness of the muscularis propria in cats with lymphoma or IBD was twice the thickness of that of healthy cats, and was the major contributor to significant overall bowel wall thickening in the duodenum and jejunum. A muscularis to submucosa ratio >1 is indicative of an abnormal bowel segment. Colic lymph nodes in cats with lymphoma were increased in size compared with healthy cats. In cats with gastrointestinal lymphoma and histologic transmural infiltration of the small intestines, colic or jejunal lymph nodes were rounded, increased in size and hypoechoic.

Accepted: 11 June 2013

Introduction

Gastrointestinal (GI) lymphoma is the most commonly encountered form of lymphoma in cats,^{1,2} and is characterized by lymphoid infiltration of the stomach and/or intestines with or without jejunal and/or colic lymph node involvement.^{1,3} There are three main histological types of GI lymphoma in cats: diffuse small cell T-cell lymphoma, considered as a low grade lymphoma; large cell B-cell lymphoma, a high grade lymphoma, which is considered more aggressive and usually involves the mesenteric lymph nodes; and large granular cell lymphoma, which is the least common form of GI lymphoma.^{4,5} Inflammatory bowel disease (IBD) is another common disorder of the small intestine in cats, which has similar presenting signs and histologic appearance to small cell T-cell intestinal lymphoma.⁶ Ultrasonography is commonly used to investigate the small intestine for evidence of disease, and a pattern of muscularis propria thickening has been recognized in cats with lymphoma and cats with IBD.^{4,7–9} This appearance is distinct from

the majority of articles describing feline GI lymphoma in the literature that describe the sonographic appearance of large cell B-cell or T-cell lymphoma, which typically causes single or multiple masses in the stomach, small intestine or colon.^{1,10,11}

¹William R Pritchard Veterinary Medical Teaching Hospital, University of California, Davis, CA, USA

²Department of Medicine and Epidemiology, School of Veterinary Medicine, University of California, Davis, CA, USA

³Department of Pathology, Microbiology and Immunology, School of Veterinary Medicine, University of California, Davis, CA, USA

⁴Clinical and Translational Science Center, School of Medicine, University of California, Sacramento, CA, USA

⁵Department of Surgical and Radiological Sciences, School of Veterinary Medicine, University of California, Davis, CA, USA

Corresponding author:

Allison Zwingenberger DVM MAS, Department of Surgical and Radiological Sciences, School of Veterinary Medicine, University of California, Davis, CA 95616, USA
 Email: azwingen@ucdavis.edu

The prevalence of muscularis propria thickening on ultrasonographic examination is higher in populations of cats with lymphoma than in IBD.⁷ Once abnormal thickening of this intestinal layer is recognized, it can serve as a biomarker to indicate the need for further diagnostics, such as biopsy of the small intestine, to confirm the diagnosis of lymphoma or IBD. Immunohistochemistry and especially clonality (T-cell receptor gene rearrangement analysis) are becoming more established for differentiating lymphoma from IBD, and can be used to reliably separate the populations to further refine imaging comparisons.^{12,13} To date, the degree of thickening of the muscularis propria in cats with small cell T-cell lymphoma or IBD relative to healthy cats has not been quantified and compared.

The aim of this study was to quantify the wall layer thickness of cats with diffuse small cell T-cell intestinal lymphoma, IBD, and healthy cats, and to compare layer alterations among groups. In addition, we sought to define a clinical guideline that would differentiate cats with diseased bowel wall segments from healthy cats.

Materials and methods

Study population

This was a prospective study that selected affected cats and healthy control cats, with partial age and breed matching. Inclusion criteria for the healthy control cats were cats older than 7 years, no history of GI illness for the last 6 months, and unremarkable complete blood count (CBC) and serum biochemistry panel. None of the control cats had any GI biopsies obtained, and serum B₁₂/folate concentrations were not determined in these cats. Healthy control cats were client-owned animals and all owners signed an informed consent form. All clinically affected cats underwent an exploratory laparotomy with full-thickness biopsies of the duodenum, jejunum, ileum and biopsy of the jejunal and/or colic lymph nodes when identified at surgery. Inclusion criteria for affected cats were a minimum database consisting of a CBC, serum biochemistry profile and urinalysis, as well as full-thickness biopsies of each bowel segment, with a histologic diagnosis of lymphoma or IBD.

Images and analysis

Abdominal ultrasound was performed on both groups of cats with the patient in dorsal recumbency. Representative ultrasonographic images were obtained using an 8–12 MHz linear electronic transducer or curvilinear 5–8 MHz transducer (ATL 5000; Philips). All cats were fasted for a minimum of 8 h and the bowel loops were free of gas. At least three images of each bowel segment (duodenum, jejunum and ileum) were obtained in transverse and sagittal planes using 1–2 focal zones in order to counteract the effects of any off-plane angulation of the images and minimize differences between

transducers. Three or more images were obtained of the jejunal and colic lymph nodes in the sagittal plane, and echogenicity and echotexture were recorded.

The images were stored as DICOM images and transferred to a software program (Osirix v. 3.9.1) to generate profile plots of pixel brightness and distance. This allowed the measurement of the thickness of each layer of the intestinal wall on a pixel-by-pixel basis. The pixel size was calibrated for each image. Three full-thickness measurements of the duodenal and jejunal walls from mucosa to serosa of one wall, as well as measurements of the thickness of each layer (mucosa, submucosa, muscularis and serosa) were performed in sagittal and transverse planes. The number of focal zones used, and the side of the wall measured (near-field or far-field) were recorded for each measurement. The thickness of the ileal muscularis propria was measured in transverse and sagittal planes. Maximal and minimal thickness of the ileal submucosa was measured in the transverse imaging plane in order to account for the natural invaginations. The thickness of the jejunal and colic lymph nodes were measured using the same software. Images that did not depict the bowel layers and boundaries clearly were discarded, and no measurements for that bowel segment were recorded.

Pathologic diagnosis

Confirmation of GI lymphoma was made based on results of histology, immunohistochemistry and polymerase chain reaction (PCR) clonality for rearrangement of T-cell receptor gamma.¹⁴ The immunohistochemistry panel consisted of CD3, CD18, CD20, CD45R, CD79a and intraepithelial-associated antigen. Bowel segments with a monomorphic population of small lymphocytes that were CD3-positive, and had a clonal or oligoclonal population of cells, were classified as feline small cell T-cell lymphoma. The GI biopsies from all IBD and lymphoma cats were interpreted by a board-certified veterinary pathologist (PFM) utilizing the World Small Animal Veterinary Association Gastrointestinal Standardization Group classification scheme.¹⁵ Specifically, all cats with IBD had a history of chronic GI disease (duration >3 weeks), a failure to respond to symptomatic therapies, exclusion of other causes of GI disease, and histologic findings consistent with a diagnosis of IBD (expansion of the lamina propria by a mixed population of small lymphocytes, lymphocytes, plasmocytes, mastocytes and macrophages; the infiltration was dispersed in the lamina propria and did not involve the crypts). Morphologic features such as villous atrophy were also documented. Each bowel segment with an exclusive histological diagnosis of T-cell lymphoma or IBD was classified as lymphoma or IBD. Segments with both diseases were excluded from analysis.

Bowel segments with lymphoma infiltrate present in the mucosa and just beyond the muscularis mucosa were classified as early transmural, and those involving the mucosa and the deeper portion of the submucosa, were classified histologically as more advanced transmural infiltrates. Bowel segments with lymphoma limited to the mucosal layer were not transmural.

Statistical analysis

We evaluated differences in the mean thickness of the intestinal segments among healthy small intestine and small intestine diagnosed with small cell T-cell lymphoma or IBD. We tested for differences in the thickness of the four intestinal layers (mucosa, submucosa, muscularis and serosa) and the full thickness of the intestinal wall with a mixed effect model. We modeled mean width as a function of diagnosis (lymphoma, IBD and healthy) and included age as a covariate. A random cat effect was included to account for the correlation among multiple measurements on the same cat. Because the intestine consists of three sections, the duodenum, jejunum and ileum, which have different characteristics, the relationships among the thicknesses of layers and lymphoma status were investigated for each segment separately. Statistical analyses were conducted using the PROC MIXED procedure in SAS v. 9.2 for Windows. We conducted all pairwise comparisons of diagnosis based on least squares means with a Tukey adjustment to maintain the type I error rate at 0.05. A significance level of 0.05 was used in hypothesis testing.

Differences in the size of jejunal and colic lymph nodes between healthy cats and cats with lymphoma were similarly analyzed. A mixed effect model was used to analyze the relationship between lymph node thickness, and the primary predictor of lymphoma status with age as a covariate and a random effect for each cat. Jejunal and colic lymph nodes were evaluated separately because of their different shapes. Statistical analyses were conducted using the PROC MIXED procedure in SAS v. 9.2 for Windows. A significance level of 0.05 was used in hypothesis testing.

For the duodenum and jejunum, we calculated the ratio of the mean thickness of the muscularis propria to the mean thickness of the submucosa for each cat using a Wilcoxon test.

Results

Study population

Data collection was performed from March 2008 to July 2011. The healthy group was composed of 19 cats: 12 females (one non-spayed) and seven castrated males. The mean age in the group was 9.70 ± 0.47 years (6.75–13.1 years). All cats were free of GI disease for a minimum of 6 months, as determined by the history and medical record. Complete blood count and serum

biochemistry was unremarkable in all cats. Follow up data (1–4 years) were available for seven of the cats, and none presented for GI signs during this interval.

The affected group was composed of 14 cats presenting to the small animal internal medicine service at UC Davis from March 2008 to July 2011 for evaluation of vomiting, diarrhea, weight loss or anorexia. The group was composed of three female spayed cats and 11 castrated male cats, with a mean age of $10.79 \text{ years} \pm 0.92$ (1.75–14.5 years).

Of the 14 affected cats, two had mixed lymphoma and IBD in one segment, and these segments were excluded from analysis. These two cats had only IBD in the remaining segments. After these exclusions, seven cats had lymphoma only (six involving all segments and one with one segment affected), six had IBD only with one ($n = 1$), two ($n = 2$) or three ($n = 3$) segments involved. One cat had both lymphoma and IBD, with lymphoma only in the jejunum and IBD only in the duodenum and ileum. All the ultrasound examinations were performed by a single sonographer (MPL). The full thickness intestinal biopsies were performed 1–20 days after ultrasonography.

All cats diagnosed with IBD underwent an elimination diet trial utilizing a diet containing a novel, single protein source or a hydrolyzed protein diet, and one cat was fed a highly digestible intestinal diet for at least 3 weeks. All cats diagnosed with IBD had a minimum database determined, which consisted of a CBC, chemistry profile and urinalysis. In addition, serum T_4 concentration was determined on all cats >4 years of age, and all cats diagnosed with IBD had measurement of serum B_{12} /folate concentrations. Serum cobalamin concentrations were below the reference interval in 2/6 cats diagnosed with IBD. A centrifugation flotation was performed on all but two cats diagnosed with IBD, and one of the two cats that did not have a fecal flotation performed was dewormed empirically with a broad spectrum anthelmintic, and the other was maintained on a monthly topical formulation for control of roundworms and hookworms for 1 year prior to evaluation. Results of fecal flotation were negative in all cats tested. An empiric antibiotic trial was instituted in 3/6 cats diagnosed with IBD, and was not associated with resolution of abnormal clinical signs. All the small intestinal biopsies were reviewed by the same pathologist (PFM).

Image analysis

The mean thickness of the muscularis propria and the full intestinal wall were significantly different among the three groups (normal segments, segments with lymphoma or segments with IBD) for the duodenum (muscularis: $F_{2,22.9} = 8.16$, $P = 0.002$; full thickness: $F_{2,22.9} = 7.87$, $P = 0.003$) and jejunum (muscularis: $F_{2,27.3} = 6.76$, $P = 0.004$; full thickness: $F_{2,27.5} = 4.08$, $P = 0.028$) (Table 1).

Table 1 Mean \pm SD thickness (cm) and (range) of intestinal wall layers of the duodenum, ileum and jejunum for normal cats, and intestinal segments affected with inflammatory bowel disease (IBD) or lymphoma

Duodenum						
Normal			Lymphoma		IBD	
Layer	n	Thickness	n	Thickness	n	Thickness
Mucosa	18	0.140 \pm 0.023 (0.099, 0.174)	5	0.170 \pm 0.036 (0.113, 0.209)	4	0.170 \pm 0.023 (0.141, 0.192)
Submucosa	18	0.040 \pm 0.007 (0.032, 0.061)	5	0.050 \pm 0.003 (0.043, 0.051)	4	0.050 \pm 0.006 (0.042, 0.055)
Muscularis	18	0.030 \pm 0.007 (0.014, 0.043)	5	0.050 \pm 0.021 (0.022, 0.068)	4	0.050 \pm 0.017 (0.028, 0.065)
Serosa	18	0.040 \pm 0.007 (0.034, 0.056)	5	0.040 \pm 0.002 (0.040, 0.044)	4	0.040 \pm 0.007 (0.033, 0.048)
Full thickness	18	0.260 \pm 0.026 (0.219, 0.306)	5	0.300 \pm 0.034 (0.268, 0.359)	4	0.310 \pm 0.033 (0.284, 0.361)
Ileum						
Normal			Lymphoma		IBD	
Layer	n	Thickness	n	Thickness	n	Thickness
Submucosa	17	0.060 \pm 0.012 (0.045, 0.080)	6	0.060 \pm 0.018 (0.051, 0.099)	5	0.070 \pm 0.013 (0.046, 0.080)
Muscularis	19	0.070 \pm 0.023 (0.032, 0.13)	6	0.090 \pm 0.022 (0.074, 0.13)	6	0.080 \pm 0.027 (0.058, 0.131)
Jejunum						
Normal			Lymphoma		IBD	
Layer	n	Thickness	n	Thickness	n	Thickness
Mucosa	19	0.130 \pm 0.024 (0.086, 0.182)	8	0.150 \pm 0.033 (0.099, 0.192)	4	0.110 \pm 0.041 (0.05, 0.143)
Submucosa	19	0.050 \pm 0.005 (0.034, 0.053)	8	0.050 \pm 0.005 (0.044, 0.057)	4	0.050 \pm 0.005 (0.045, 0.055)
Muscularis	19	0.030 \pm 0.011 (0.015, 0.054)	8	0.060 \pm 0.032 (0.023, 0.110)	4	0.060 \pm 0.017 (0.047, 0.083)
Serosa	19	0.050 \pm 0.004 (0.037, 0.052)	7	0.040 \pm 0.007 (0.037, 0.059)	4	0.040 \pm 0.003 (0.038, 0.044)
Full thickness	19	0.260 \pm 0.028 (0.202, 0.314)	8	0.300 \pm 0.045 (0.233, 0.356)	4	0.250 \pm 0.053 (0.185, 0.300)

For the duodenum, the thickness of the muscularis propria and the full thickness of the intestinal wall were significantly thicker in cats with IBD or lymphoma than healthy cats (muscularis: $P = 0.006$ and $P = 0.015$, respectively; full thickness: $P = 0.009$ and $P = 0.012$, respectively) (Table 1). For the jejunum, both the muscularis propria ($P = 0.011$) and the full wall thickness ($P = 0.023$) were thicker in cats with lymphoma than healthy cats, but only the muscularis propria differed significantly in IBD cats versus healthy cats ($P = 0.046$) (Table 1). The thickness of the other three layers (mucosa, submucosa and serosa) did not differ significantly by diagnosis status in the duodenum and jejunum (Table 1). Thus, increased thickness

of the muscularis propria is the primary contributor to the significant difference in the total width of the intestinal wall for these sections. In the ileum, only measurements for the submucosa and muscularis propria were obtained owing to the poor visibility of the luminal border. The thickness of these layers did not differ significantly by diagnosis status (Table 1). In no cases did IBD cats differ significantly from cats with lymphoma. The age of the cat was a significant covariate for submucosa ($P = 0.006$) and muscularis ($P = 0.021$) layers in the ileum, and for full thickness ($P = 0.004$) in the jejunum.

Although the mean thickness of the muscularis propria and the full-thickness intestinal wall differed

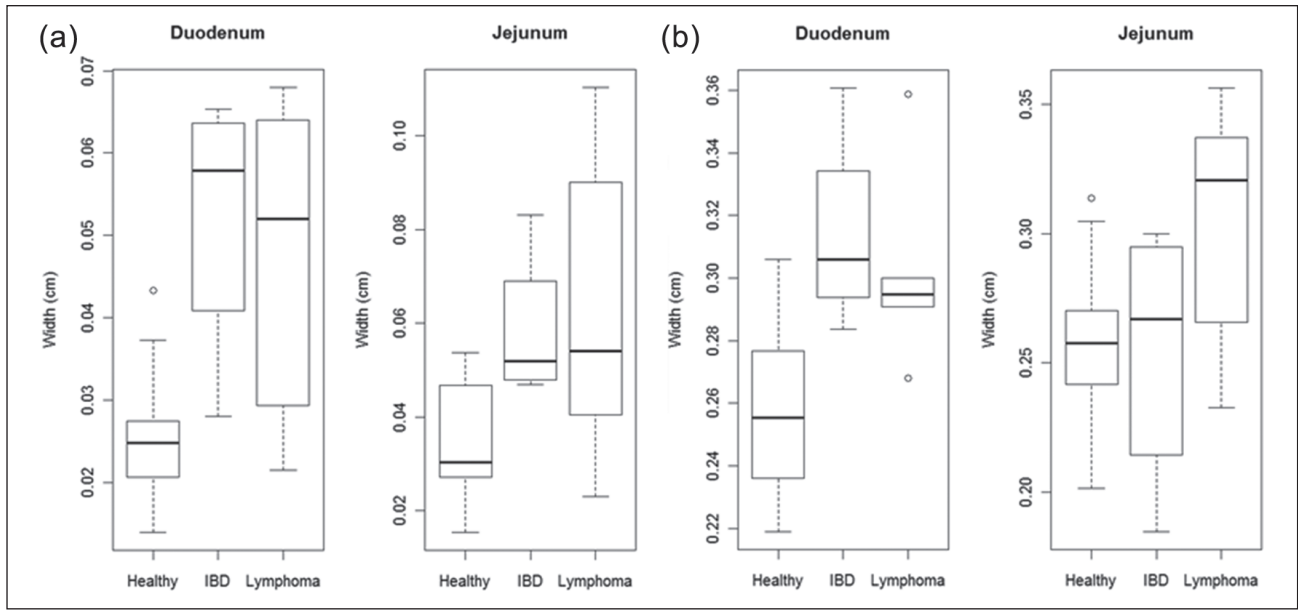


Figure 1 Thickness (cm) of the muscularis propria (a) and the full intestinal wall (b) in the duodenum and jejunum for healthy cats and cats with lymphoma or inflammatory bowel disease

Table 2 Results of ratio comparisons of the mean thickness (cm) of the muscularis to the submucosa for each cat in the duodenum and jejunum in bowel segments of healthy cats and segments affected with lymphoma or inflammatory bowel disease (IBD)

	Healthy: lymphoma		Healthy: IBD	
	W	P	W	P
Duodenum	21	0.080	5	0.005*
Jejunum	35	0.019*	9.5	0.023*

*Indicates significant difference between groups

significantly by lymphoma status, thickness measurements from the healthy and affected groups overlapped (Figure 1). The thickness of the muscularis propria and the full-thickness intestinal wall were more variable in cats with lymphoma than in healthy cats, and the thickness of the muscularis propria and full-thickness intestinal wall in some of the cats diagnosed with lymphoma were similar to healthy cats. Nevertheless, the largest thickness for the muscularis and full-thickness intestinal wall were from cats with lymphoma (Table 1).

For the duodenum and jejunum, we calculated the ratio of the mean thickness of the muscularis propria to the mean thickness of the submucosa for each cat. A Wilcoxon (W) test found healthy cats to have a significantly lower ratio than cats with IBD only for the duodenum (W = 5, P = 0.005) and jejunum (W = 9.5, P = 0.023), and also for cats with lymphoma in the jejunum (W = 35, P = 0.029), but not significant for the duodenum (W = 21, P = 0.080) (Table 2; Figure 2). For the duodenum and jejunum, we also calculated the ratio of the

mean width of the muscularis to the mean width of the mucosa for each cat. The muscularis propria:mucosa ratio was not found to be significantly different between segments of healthy cats and cats with lymphoma or IBD in the duodenum and jejunum (Figure 3).

The most common location for GI lymphoma was the jejunum (eight segments). For IBD, the duodenum was the most frequently involved segment (seven segments). The IBD was classified as moderate in the duodenum for five cats and mild for one cat. In the jejunum, three cats had moderate IBD and one had mild IBD. In the ileum, two cats had moderate IBD, three had mild IBD and two had a normal biopsy. All bowel segments affected with lymphoma had early transmural disease, except for two segments in one cat, which had mucosal involvement only.

Six lymph node biopsies were obtained surgically from the eight cats with intestinal segments containing lymphoma. Only two cats with IBD had visible lymph nodes at surgery that were able to be collected, which

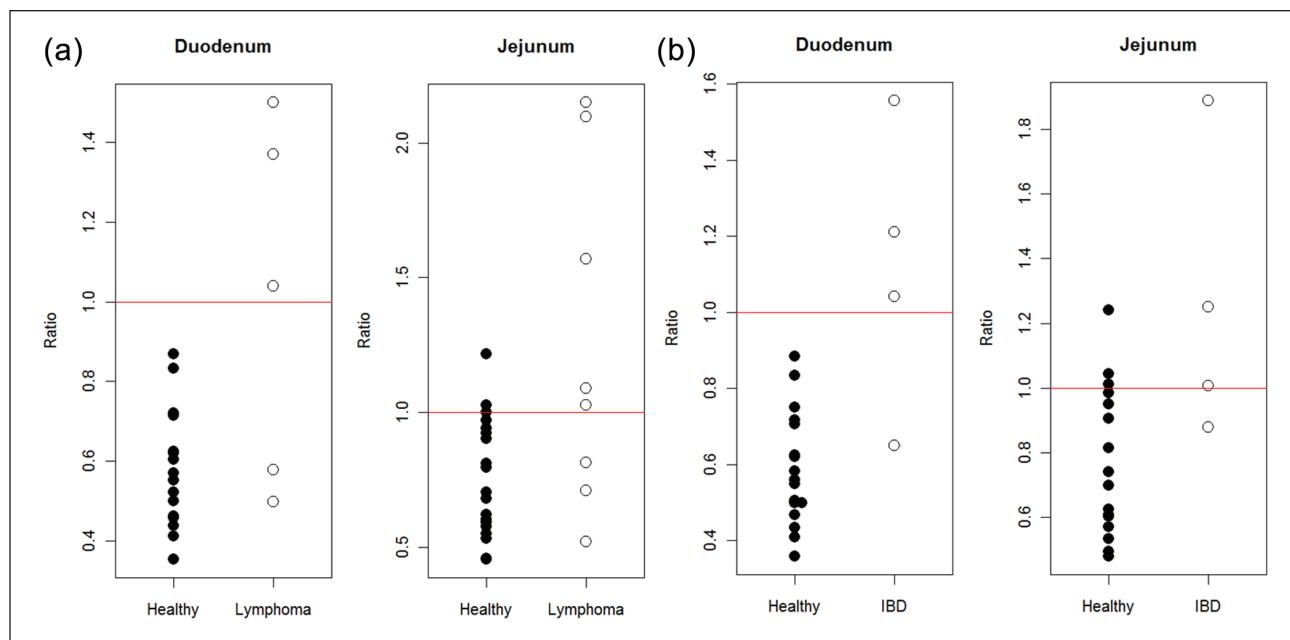


Figure 2 Ratio of the mean thickness (cm) of the muscularis to the submucosa in the duodenum and jejunum in healthy cats and intestinal segments affected with lymphoma (a) or inflammatory bowel disease (IBD) only (b). A ratio >1 is suggestive of lymphoma or IBD

was insufficient for statistical analysis. Owing to storage of each cat's surgical biopsies in a single container, jejunal and colic lymph nodes were not differentiated histologically. Lymph nodes from two cats had a monoclonal population of lymphocytes identical to the population present in the affected intestines based on PCR clonality for rearrangement of the T-cell receptor, indicating metastatic disease. These two lymph nodes were associated with marked transmural infiltration of the ileum in one cat and of the jejunum in the other cat. These lymph nodes were also the largest measured ultrasonographically (0.67 cm versus a mean of 0.26 cm in healthy cats). The remainder of the lymph nodes was diagnosed as reactive. Colic lymph nodes were significantly larger in cats with lymphoma than in healthy cats ($F_{1,22,9} = 9.38$, $P = 0.005$), but the width of jejunal nodes did not differ significantly by lymphoma status ($F_{1,24,7} = 2.78$, $P = 0.108$). Similar to the intestinal width measurements, lymph node width was more variable in cats with lymphoma than in healthy cats (Table 3). As found for the width of the intestinal layers, age was not a significant predictor of lymph node width ($P > 0.05$).

Discussion

Feline GI small cell T-cell lymphoma is becoming recognized as a distinct form of GI lymphoma in cats,^{4,5,9,12,16} and appears similar to IBD on ultrasound and histology. Both IBD and lymphoma are characterized by diffuse or segmental distribution in the small intestine, with ultrasonographic features of bowel wall thickening owing to

increase of the muscularis propria and preservation of wall layers without mass formation. In our study, the muscularis propria was twice as thick in intestinal segments with lymphoma and IBD than in healthy cats (Figure 1), and was the major contributor to overall bowel wall thickening. We also found that the ratio of the width of the muscularis to submucosa is usually <1 in unaffected cats, but usually >1 in segments with lymphoma or IBD. Finally, colic lymph nodes in cats with lymphoma were increased in size compared with healthy cats. The mean width of colic lymph nodes measured 0.41 cm in the lymphoma cats versus 0.20 cm in healthy cats.

GI lymphoma was most commonly found in the jejunum, and IBD was localized most frequently in the duodenum. This distribution of disease is in agreement with previous studies.^{3,4,16} The ileum and duodenum were affected by lymphoma at a similar frequency in our study, which differs from another study in which the ileum was affected less frequently.⁴ These discrepancies may be related to the small number of cases enrolled in both studies.⁴

We elected to group the intestinal segments by diagnosis rather than the individual cats owing to the high prevalence of IBD in conjunction with lymphoma. The exclusion of segments with mixed disease allowed us to confidently compare lymphoma and IBD. Although there is the possibility of biopsy sampling error resulting in including a segment with mixed disease being present in the study groups, this possibility, and the effect of

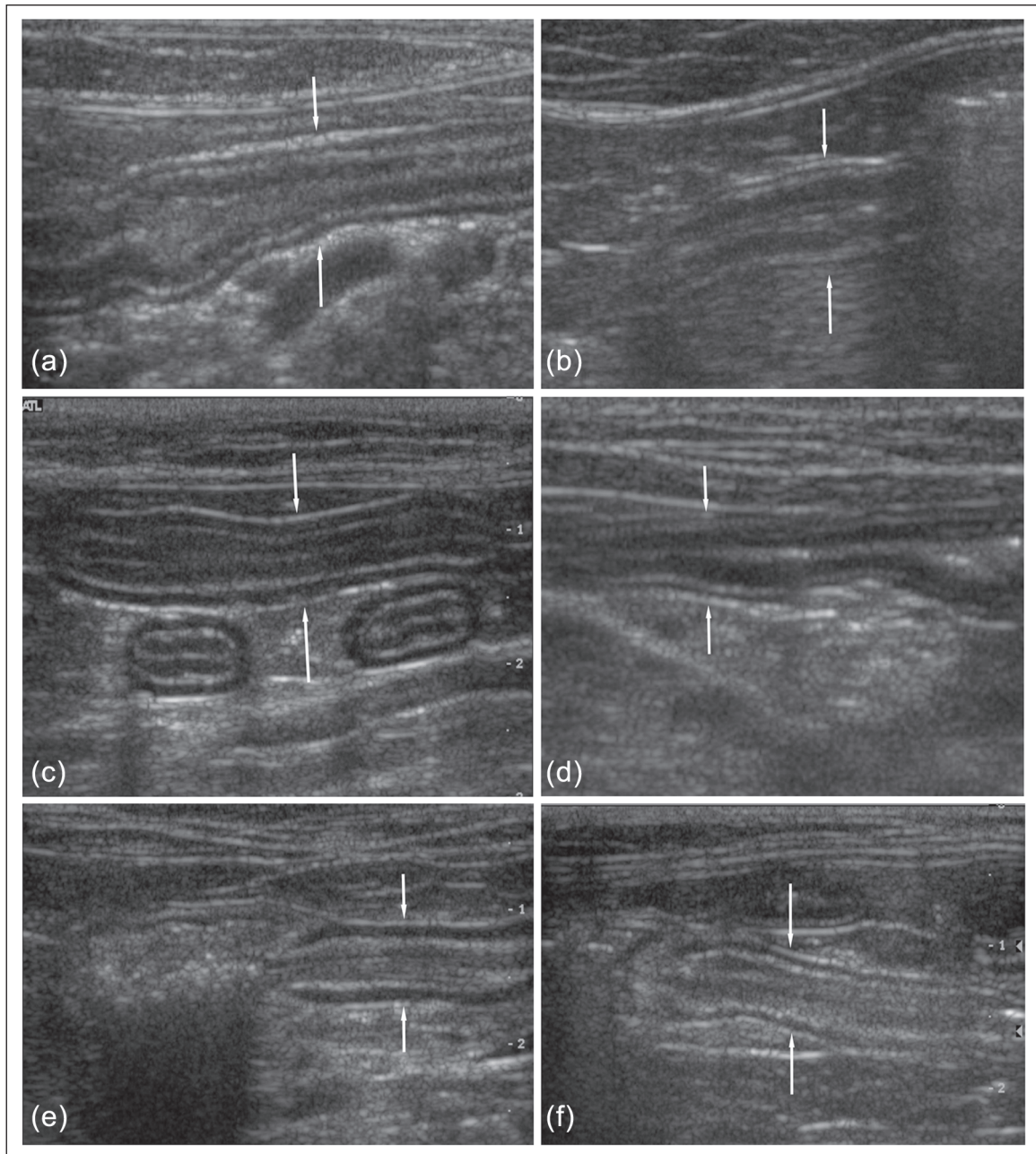


Figure 3 Ultrasonographic longitudinal images of the duodenum (a, b), jejunum (c, d) and ileum (e, f). The images on the left are of cats with lymphoma (a, c, e). Arrows denote the serosal surfaces of the sagittal bowel images. The conspicuity of the normal intestinal segments is decreased owing to their smaller size and thinner muscularis propria. (b, d, f) The muscularis propria of a cat affected with lymphoma (c) has a muscularis:submucosa ratio >1 , while the ratio in the normal cat (d) is <1 . There was a trend to thicker muscularis propria in the ileum in cats with lymphoma (e) compared with normal cats (f)

such, is felt to be small. The specificity of the immunohistochemistry and clonality analysis makes the differentiation of IBD from lymphoma very strongly supported in this group of samples.

The major GI ultrasonographic finding in intestinal segments with T-cell lymphoma and IBD was a diffuse circumferential thickening of the muscularis propria layer of the small intestine. The other layers of the

intestinal wall did not differ significantly between the affected and healthy cats. These results are in accordance with a previous study in cats with diffuse small cell T-cell GI lymphoma,⁷ where the main change noted on ultrasonographic examination was muscularis propria thickening. There was a relationship between the age of the cat and the width of the submucosa and muscularis layer in the ileum, and of the full intestinal thickness in

Table 3 Mean \pm SE and (range) of thickness (cm) of lymph nodes in healthy cats and cats with lymphoma. Significance gives the F statistic and *P*-value for a difference in lymph node thickness between healthy and lymphoma cats

Type	Healthy		Lymphoma		Significance
	n	Mean \pm SE	n	Mean \pm SE	
Jejunal	18	0.34 \pm 0.120 (0.152, 0.630)	8	0.48 \pm 0.220 (0.232, 0.872)	$F_{1,24.7} = 2.78, P = 0.108$
Colic	17	0.26 \pm 0.046 (0.180, 0.338)	7	0.38 \pm 0.159 (0.204, 0.667)	$F_{1,22.9} = 9.38, P = 0.005$

the jejunal segments. There was, however, substantial variation of this general trend. Adjusting for potential confounding effects of age was important for the statistical analysis in order to isolate disease effects. However, the study was not designed to investigate changes in the thickness of the intestinal wall as a function of age, and this effect may require further studies to interpret the findings.

No cats in the present study had lymphocytic infiltrates in the muscularis layer of the intestinal segments, indicating that the presence of lymphoma cells in the muscularis propria cannot explain the increased thickness of this layer. No cats in the IBD group had disease deeper than the mucosal layer. A relationship between the thickness of the muscularis layer and the extent of the neoplastic lymphocytic infiltration has been described previously,⁷ with the muscularis thickening giving increased odds of transmural disease to the depth of the submucosa. This is supported by the current results in which the majority of bowel segments had transmural disease histologically. However, the lack of deeper disease in the IBD group indicates that there are other factors affecting the appearance of the muscularis propria on ultrasonography. A muscular hypertrophy or a muscular shortening may cause the noticeable muscularis propria thickening, as a similar, but more severe, thickening has been described in cats with muscularis hypertrophy.^{7,17} A limitation of our diagnostic methods is that full-thickness biopsy is often not performed in the true cross-sectional plane, and after tissue sectioning the angle may be altered further. This has hindered us from directly comparing histologic measurements of the bowel layers to imaging measurements. Image sampling and pathologic sampling at a more precise and correlated site within the bowel segment is also not practical. Despite the lack of histologic correlation, muscularis propria thickening is promising as an imaging biomarker of feline small cell T-cell lymphoma and IBD. However, muscularis propria thickening can be seen in other intestinal disorders. This marker should be interpreted in light of all of the clinical data.

The ratio of the muscularis propria to the submucosa may serve as a useful marker for possible infiltration

with lymphoma or IBD on ultrasonographic examination. Healthy cats had a ratio of <1 in the duodenum, and most healthy cats had a ratio of <1 in the jejunum. In contrast, the ratio of the muscularis propria to the submucosa in most cats affected with lymphoma was >1 in both segments. The ratio was significantly lower in healthy cats than in IBD cats in the duodenum and jejunum, as well as the jejunum of cats affected with lymphoma. This measure may be useful in identifying cats with muscularis propria thickening in addition to absolute measurements.

The cranial mesenteric lymphocenter includes the jejunal and colic lymph nodes. The jejunal lymph nodes drain the jejunum, ileum and the pancreas, and the colic lymph nodes drain the ileum, cecum and colon.¹⁸ The colic lymph nodes in cats with lymphoma were significantly enlarged compared with the lymph nodes of control cats (1.58 \times). Because lymph node enlargement has been associated with transmural small-cell T-cell lymphoma,⁷ both the jejunal and colic lymph nodes associated with the transmurally-affected jejunal and ileal segments would be expected to be enlarged. Interestingly, there was no significant difference in the size of the jejunal lymph nodes between healthy cats and cats with lymphoma. All eight cats with intestinal segments affected with lymphoma had jejunal disease, and 7/8 cats had transmural lymphoma infiltration. The lack of enlargement of the jejunal lymph nodes on ultrasound images correlated with the small number of lymph nodes affected with metastatic disease. The majority of the lymph nodes in the cranial mesenteric lymphocenter were affected with reactive hyperplasia. Ultrasonographically, the largest lymph nodes (colic and jejunal) were consistently associated with a histologic transmural infiltrate of the intestinal wall. Diffuse thickening of the muscularis layer of the small intestine with concurrent enlargement of the colic lymph nodes was associated with small cell T-cell GI lymphoma, although lymph node enlargement was not necessarily diagnostic for metastatic disease.

The distal distribution of lymphoma and IBD in the jejunum and ileum in many cats in our study supports the recommendation of full-thickness biopsy for the

diagnosis of feline small intestinal T-cell lymphoma and IBD. The superiority of full-thickness biopsy in the diagnosis of lymphoma is owing to the accessibility of more distal bowel segments, such as the jejunum and the ileum, which are the most commonly affected in case of small cell T-cell lymphoma.⁸ Furthermore, in biopsies obtained by endoscopy at the mucosal level, transmural infiltrate can often not be determined.

Lymphoma with concurrent lymphoplasmacytic IBD in a single intestinal segment was diagnosed in two cats, and in different segments in one cat. This result was in accordance with previous studies that demonstrated IBD and lymphoma commonly occur together.^{4,9,16} It has been postulated by multiple authors^{4,19} that the chronic inflammatory process precedes, and acts as a trigger for, the subsequent onset of GI lymphoma. This was also reported by Moore et al,¹⁴ where 60% of the cats with lymphoma had prior clinical signs indicative of IBD. That this is a possible continuum of disease may relate to the similarity of the ultrasonographic appearance of muscularis propria in both populations. In addition, ultrasound is used as a screening test for clinical decision-making for full-thickness biopsy, and this imaging appearance may have produced a sampling bias.

This clinical study balanced the best interests of the healthy control group with the limitations posed by alternative measures of GI health when choosing whether to procure intestinal biopsies. We felt that the combination of tests used to enroll the healthy control group were reasonable indicators of small bowel health. The limitations of the methods used may have included cats with sub-clinical intestinal disease into the healthy control group, possibly resulting in some of the overlapping ranges of bowel wall thickness. However, 7/19 healthy control cats were re-evaluated at University of California, Davis, during the ensuing 4 years for unrelated reasons, and had no evidence of weight loss, vomiting or diarrhea.

Our study compared the wall-layering of cats with IBD to intestinal lymphoma, and found no ultrasonographic differences between the diseases. A previous study found a stronger association between lymphoma and muscularis thickening than IBD when considering the prevalence in each population. Therefore, the presence of muscularis propria thickening is more often seen in cats with small cell T-cell lymphoma, but the current study confirmed that the imaging appearance was the same in each disease when ultrasonographic abnormalities were present. Both disease groups were clearly different from the population of healthy cats, and the ratio of muscularis propria to submucosa of >1 was indicative of small intestinal disease.

Conclusions

There was a significant increased thickness of the intestinal wall and muscularis propria layer in the small

intestines of cats with GI small cell T-cell lymphoma and IBD. A muscularis/submucosa ratio of >1 was likely to be associated with GI lymphoma or IBD in this population of cats.

Funding This study was supported by the Center for Companion Animal Health (CAAH), School of Veterinary Medicine, University of California, Davis, and Grant Number UL1 RR024146 from the National Center for Research Resources (NCRR), a component of the National Institutes of Health (NIH), and NIH Roadmap for Medical Research. Its contents are solely the responsibility of the authors and do not necessarily represent the official view of NCRR or NIH. Information on NCRR is available at <http://www.ncrr.nih.gov/>. Information on Re-engineering the Clinical Research Enterprise can be obtained from <http://nihroadmap.nih.gov/clinicalresearch/overview-translational.asp>.

Conflict of interest The authors do not have any potential conflicts of interest to declare.

References

- Mahony OM, Moore AS, Cotter SM, et al. **Alimentary lymphoma in cats: 28 cases (1988–1993).** *J Am Vet Med Assoc* 1995; 207: 1593–1598.
- Gabor LJ, Malik R and Canfield PJ. **Clinical and anatomical features of lymphosarcoma in 118 cats.** *Aust Vet J* 1998; 76: 725–732.
- Kleinschmidt S, Harder J, Nolte I, et al. **Chronic inflammatory and non-inflammatory diseases of the gastrointestinal tract in cats: diagnostic advantages of full-thickness intestinal and extraintestinal biopsies.** *J Feline Med Surg* 2010; 12: 97–103.
- Lingard AE, Briscoe K, Beatty JA, et al. **Low-grade alimentary lymphoma: clinicopathological findings and response to treatment in 17 cases.** *J Feline Med Surg* 2009; 11: 692–700.
- Fondacaro JV, Richter KP, Carpenter JL, et al. **Feline gastrointestinal lymphoma: 67 cases (1988–1996).** *Eur J Comp Gastroenterol* 1999; 4: 5–11.
- Willard MD. **Feline inflammatory bowel disease: a review.** *J Feline Med Surg* 1999; 1: 155–164.
- Zwingenberger AL, Marks SL, Baker TW and Moore PF. **Ultrasonographic evaluation of the muscularis propria in cats with diffuse small intestinal lymphoma or inflammatory bowel disease.** *J Vet Intern Med* 2010; 24: 289–292.
- Evans SE, Bonczynski JJ, Broussard JD, et al. **Comparison of endoscopic and full-thickness biopsy specimens for diagnosis of inflammatory bowel disease and alimentary tract lymphoma in cats.** *J Am Vet Med Assoc* 2006; 229: 1447–1450.
- Carreras JK, Goldschmidt M, Lamb M, et al. **Feline epitheliotropic malignant lymphoma: 10 cases (1997–2000).** *J Vet Intern Med* 2003; 17: 326–331.
- Grooters AM, Biller DS, Ward H, et al. **Ultrasonographic appearance of feline alimentary lymphoma.** *Vet Radiol Ultrasound* 1994; 35: 468–472.
- Penninck DG, Moore AS, Tidwell AS, et al. **Ultrasonography of alimentary lymphosarcoma in the cat.** *Vet Radiol Ultrasound* 1994; 35: 299–306.

- 12 Moore PF, Rodriguez-Bertos A and Kass PH. **Feline gastrointestinal lymphoma: mucosal architecture, immunophenotype, and molecular clonality.** *Vet Pathol* 2012; 49: 658–668.
- 13 Kiupel M, Smedley RC, Pfent C, et al. **Diagnostic algorithm to differentiate lymphoma from inflammation in feline small intestinal biopsy samples.** *Vet Pathol* 2011; 48: 212–222.
- 14 Moore PF, Woo JC, Vernau W, et al. **Characterization of feline T cell receptor gamma (TCRG) variable region genes for the molecular diagnosis of feline intestinal T cell lymphoma.** *Vet Immunol Immunopathol* 2005; 106: 167–178.
- 15 Washabau RJ, Day MJ, Willard MD, et al. **Endoscopic, biopsy, and histopathologic guidelines for the evaluation of gastrointestinal inflammation in companion animals.** *J Vet Intern Med* 2010; 24: 10–26.
- 16 Briscoe KA, Krockenberger M, Beatty JA, et al. **Histopathological and immunohistochemical evaluation of 53 cases of feline lymphoplasmacytic enteritis and low-grade alimentary lymphoma.** *J Comp Pathol* 2011; 145: 187–198.
- 17 Diana A, Pietra M, Guglielmini C, et al. **Ultrasonographic and pathologic features of intestinal smooth muscle hypertrophy in four cats.** *Vet Radiol Ultrasound* 2003; 44: 566–569.
- 18 Evans HE. *Miller's anatomy of the dog.* 3rd ed. Saunders, Philadelphia, 1993, p 1113.
- 19 Waly NE, Gruffydd-Jones TJ, Stokes CR and Day MJ. **Immunohistochemical diagnosis of alimentary lymphomas and severe intestinal inflammation in cats.** *J Comp Pathol* 2005; 133: 253–260.