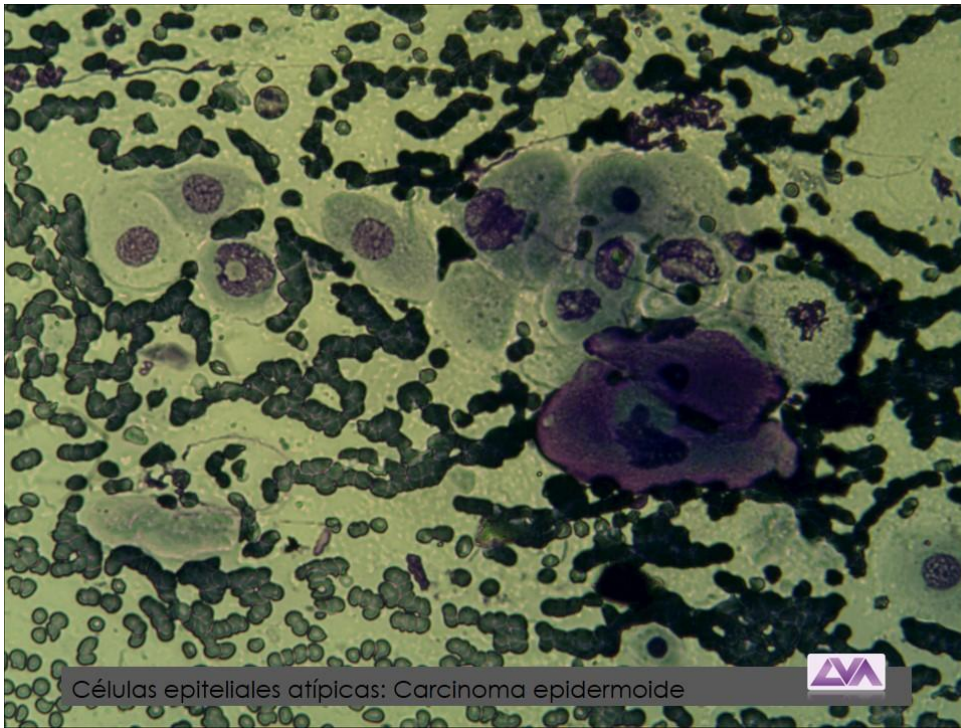


CURSO INTENSIVO EL ABC DE LA CITOLOGIA EN MEDICINA VETERINARIA

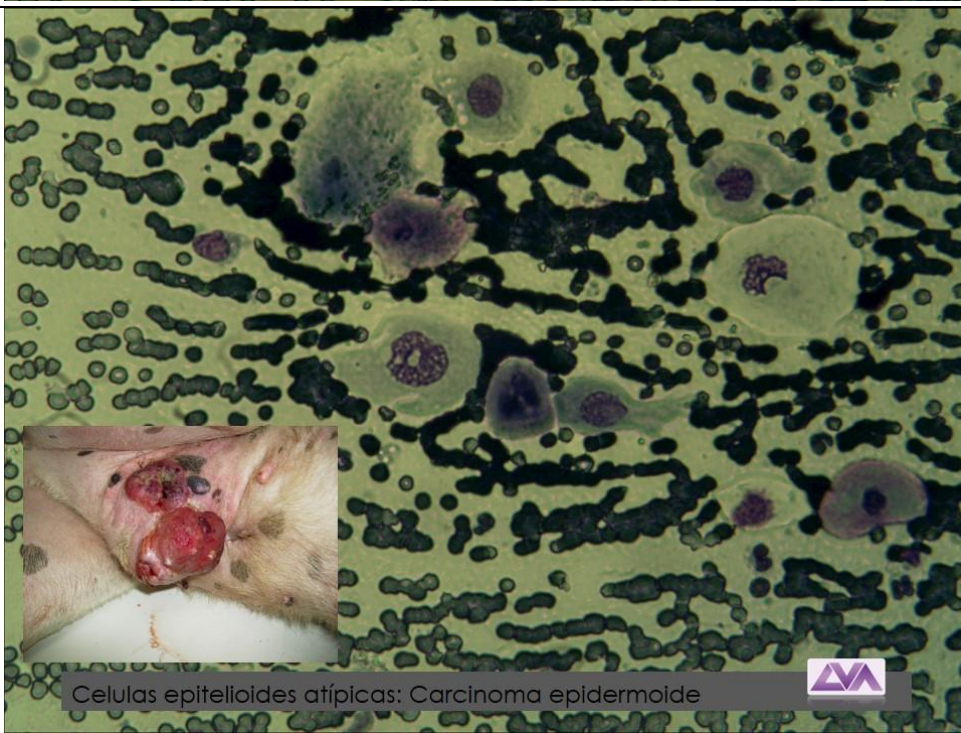
Docente M.V. Marcelo Alonso

Modalidad Online

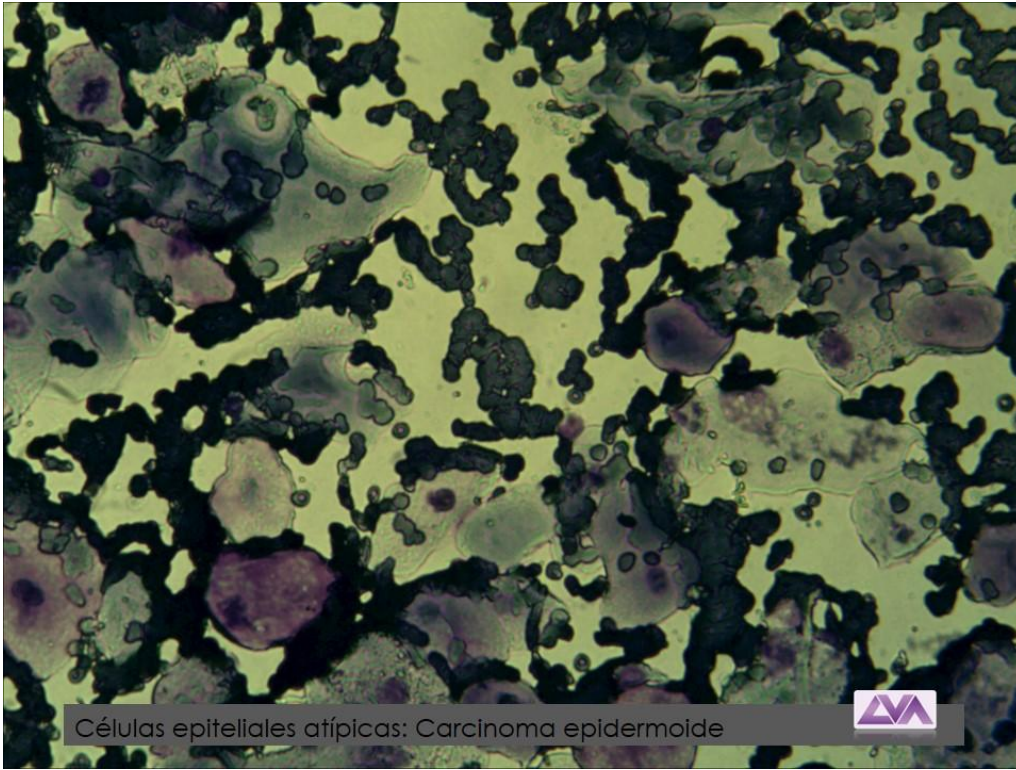
ATLAS DE CELULAS EPITELIALES



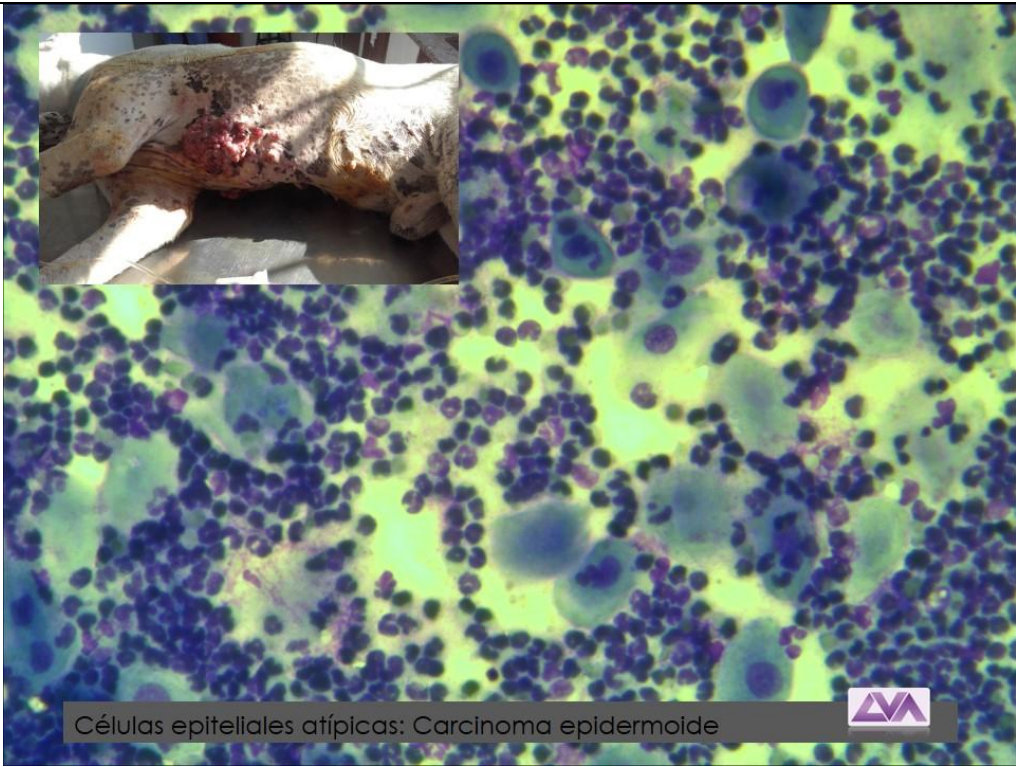
Células epiteliales atípicas: Carcinoma epidermoide



Celulas epiteloides atípicas: Carcinoma epidermoide

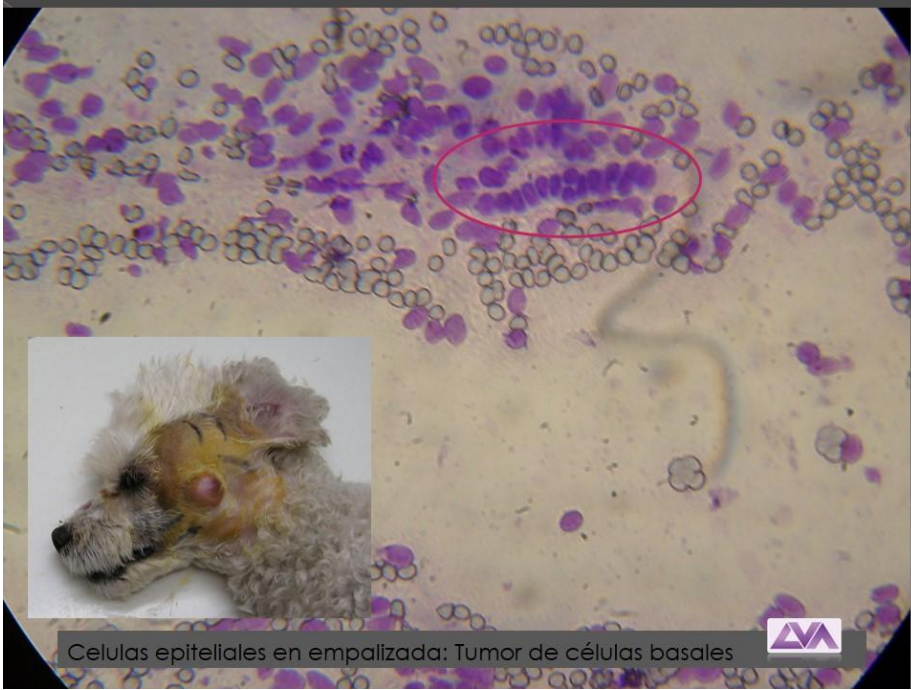


Células epiteliales atípicas: Carcinoma epidermoide

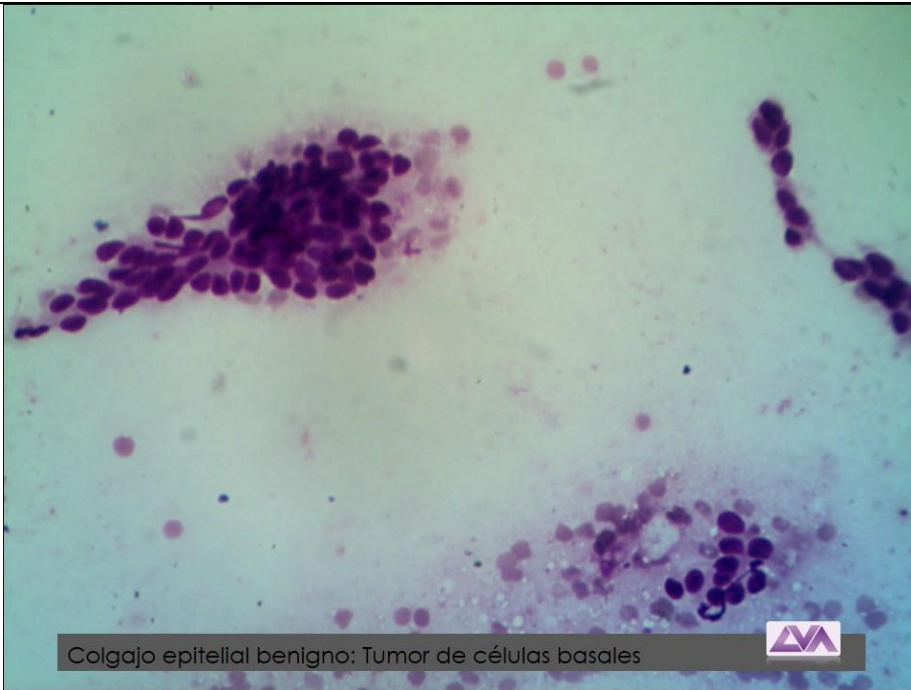


Células epiteliales atípicas: Carcinoma epidermoide



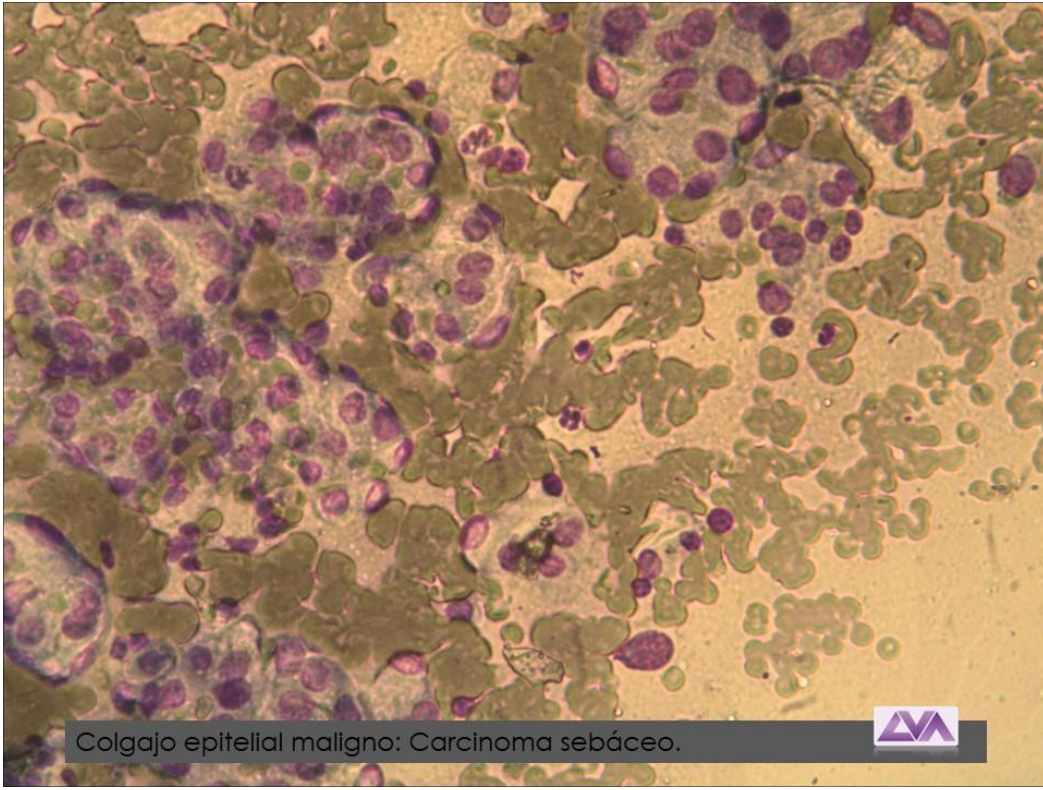


Celulas epiteliales en empalizada: Tumor de células basales

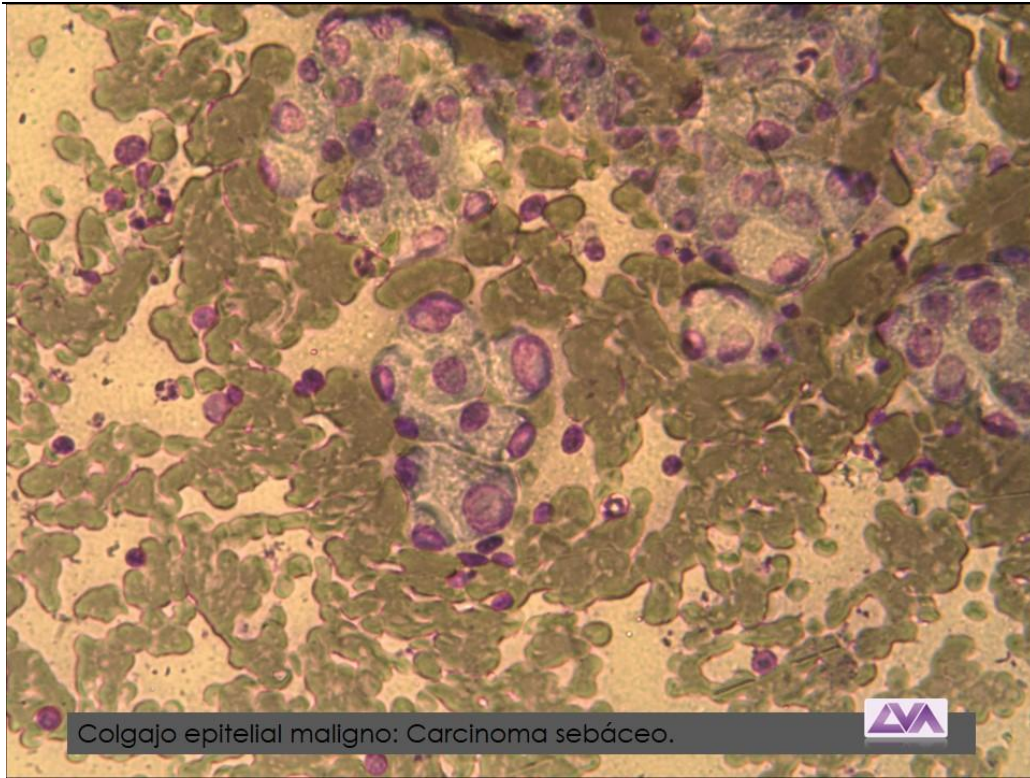


Colgajo epitelial benigno: Tumor de células basales

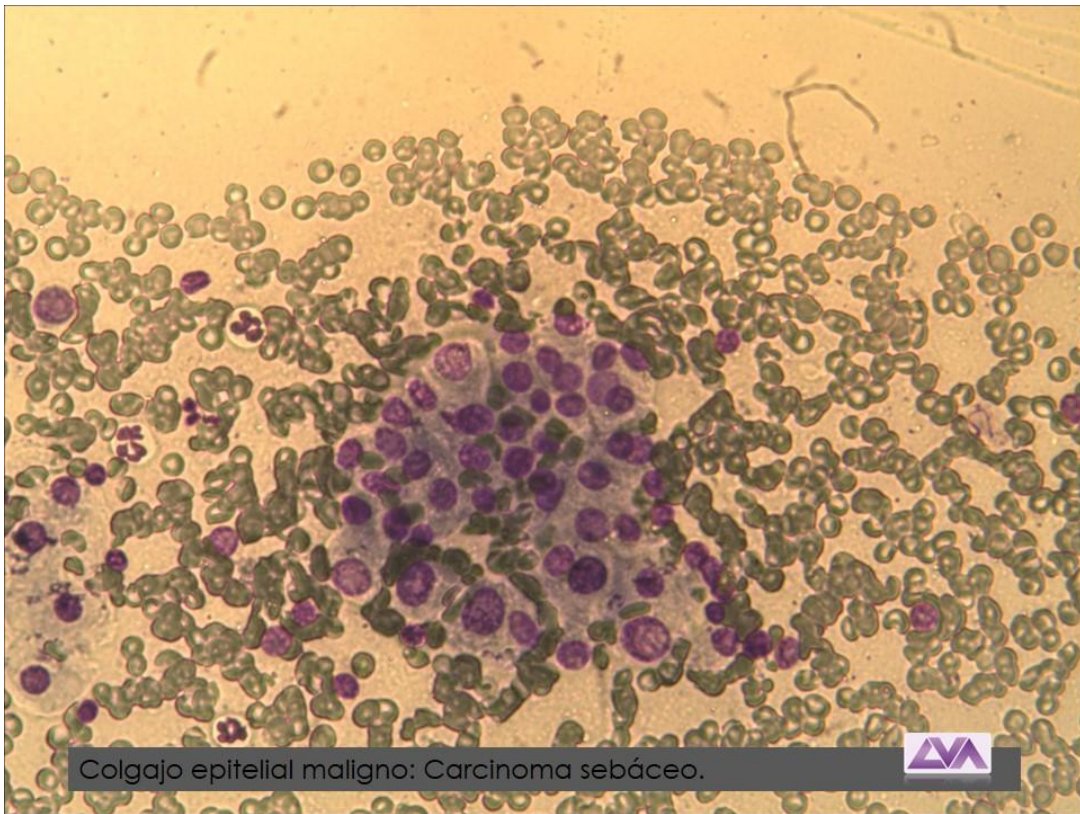




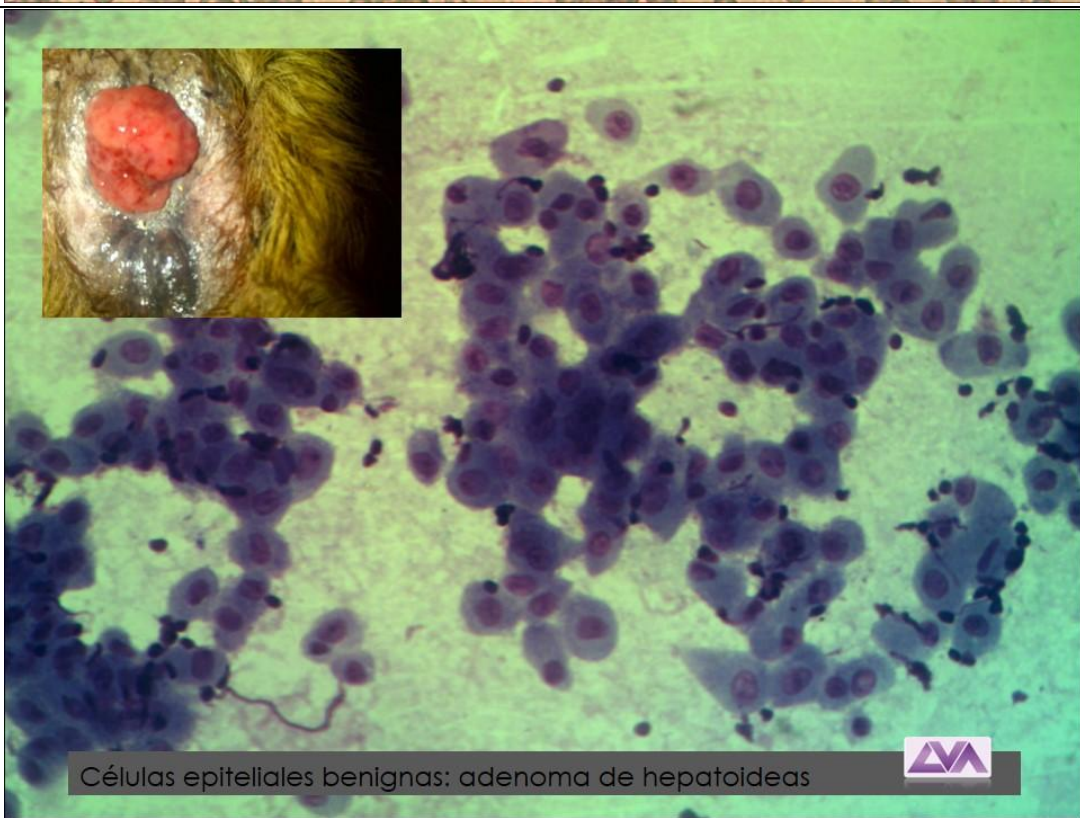
Colgajo epitelial maligno: Carcinoma sebáceo.



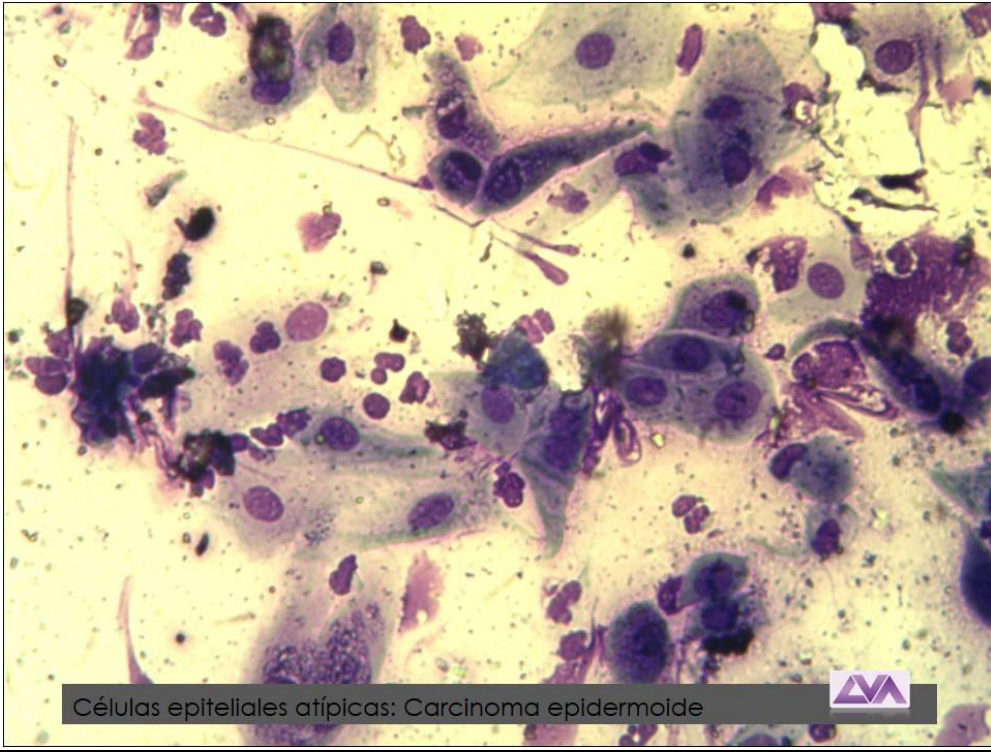
Colgajo epitelial maligno: Carcinoma sebáceo.



Colgajo epitelial maligno: Carcinoma sebáceo.



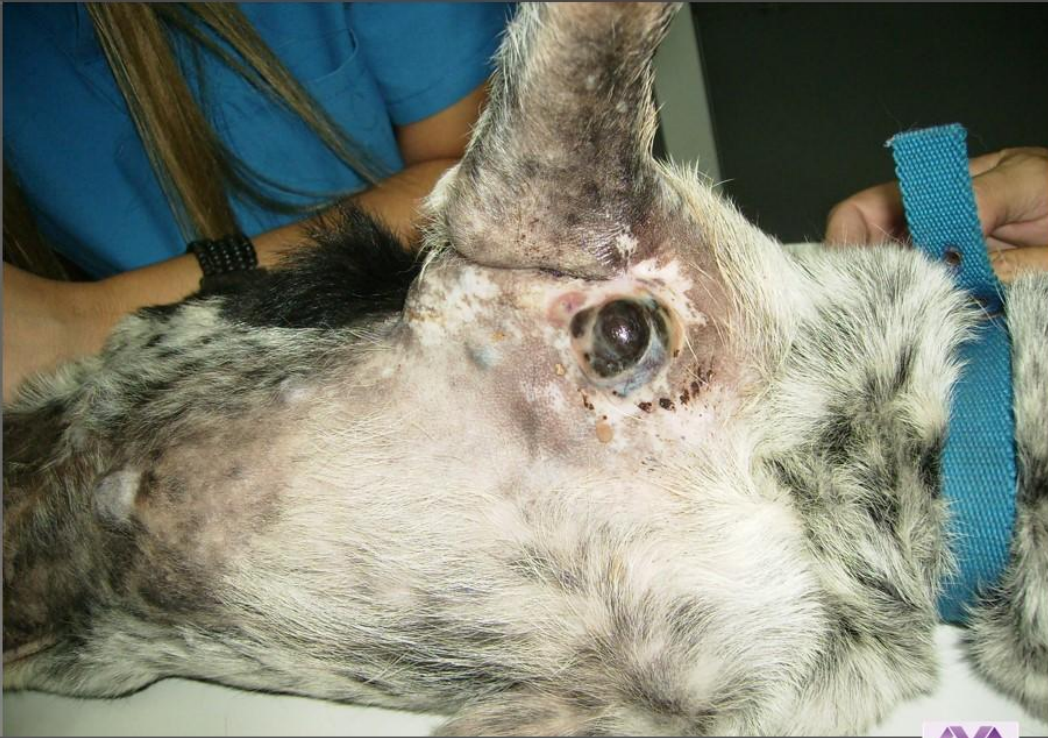Células epiteliales benignas: adenoma de hepatoideas



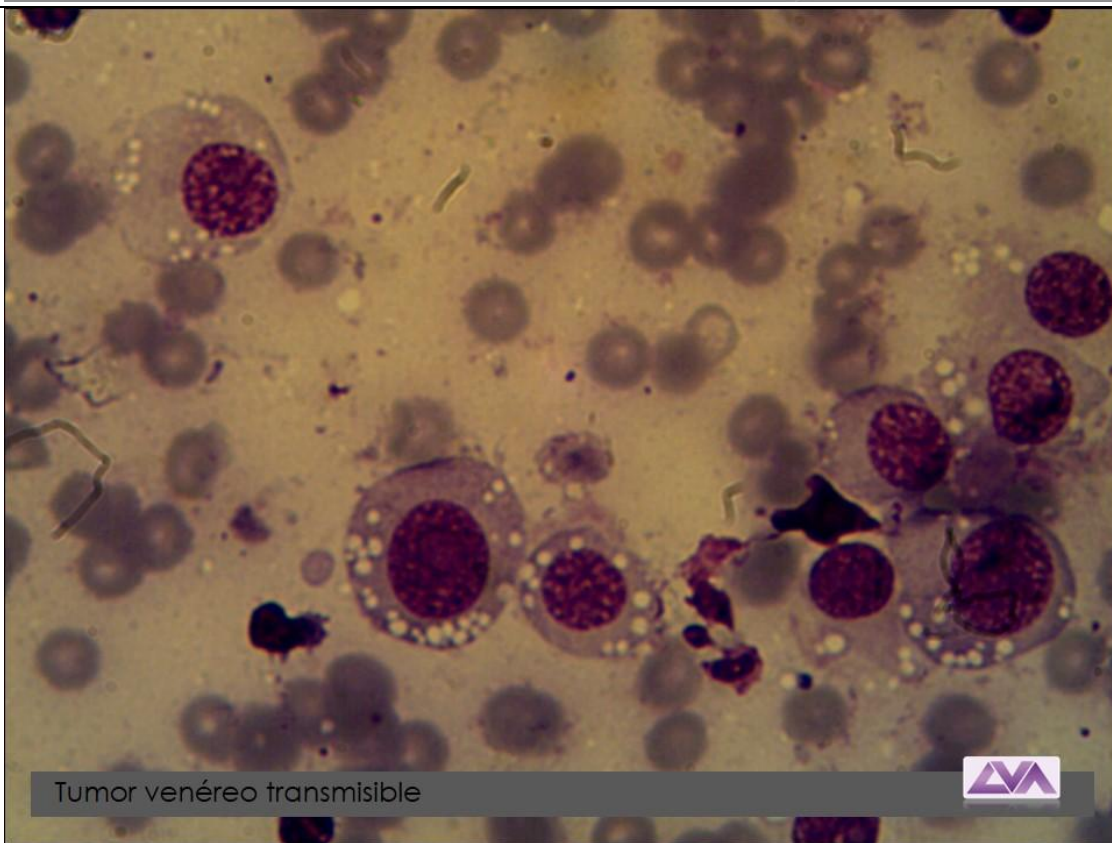
Células epitellales atípicas: Carcinoma epidermoide



ATLAS CELULAS REDONDAS

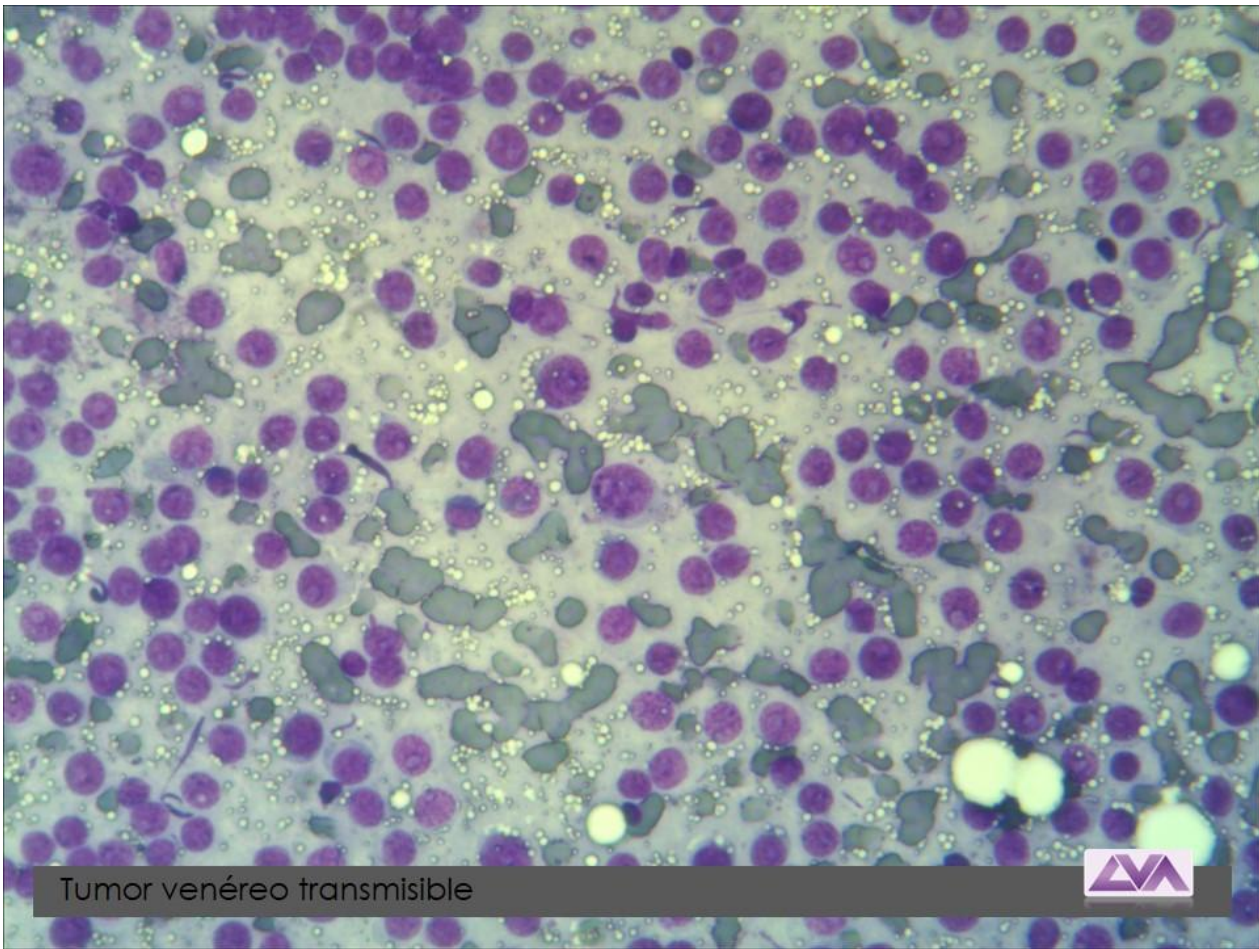


Melanoma maligno

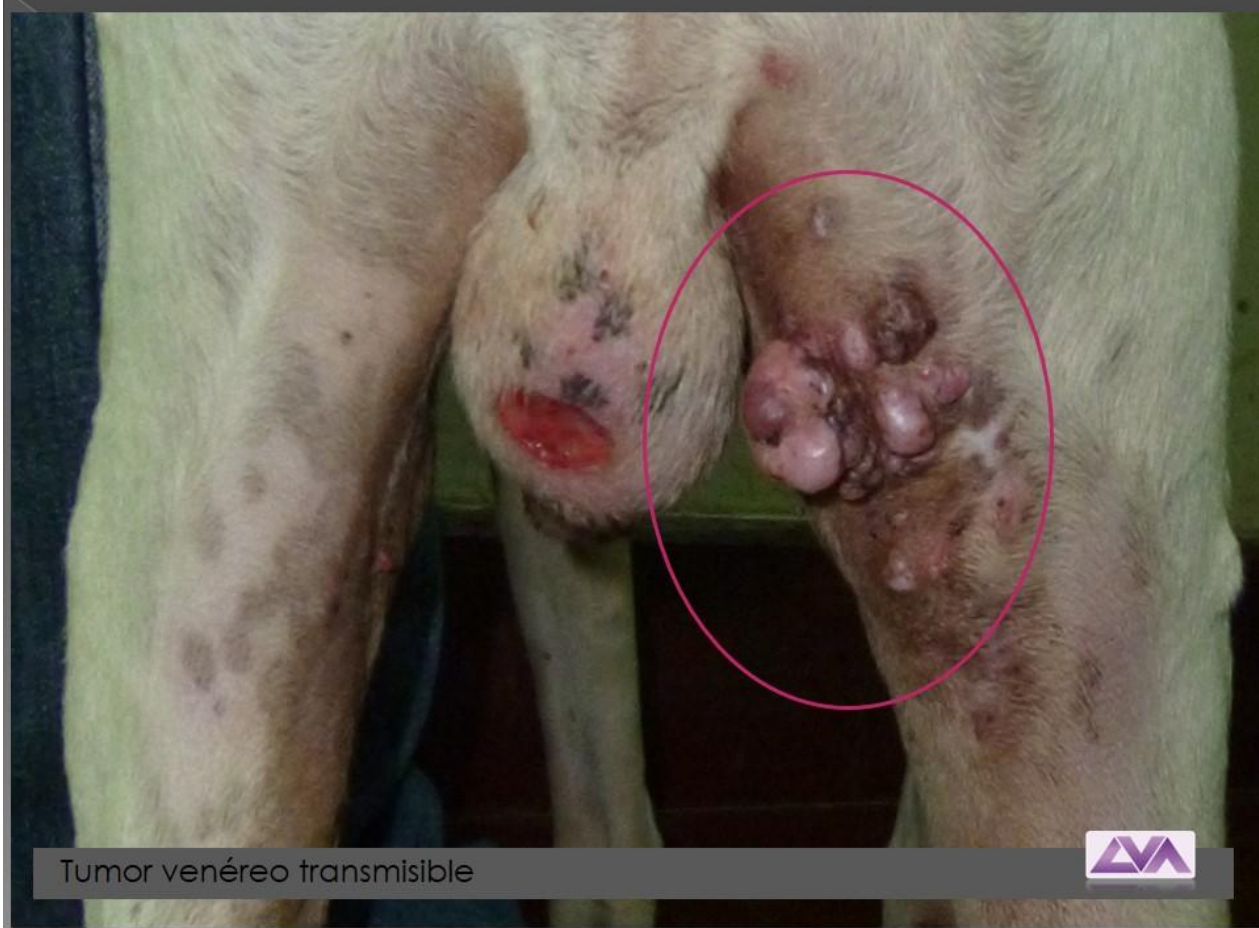

Tumor venéreo transmisible



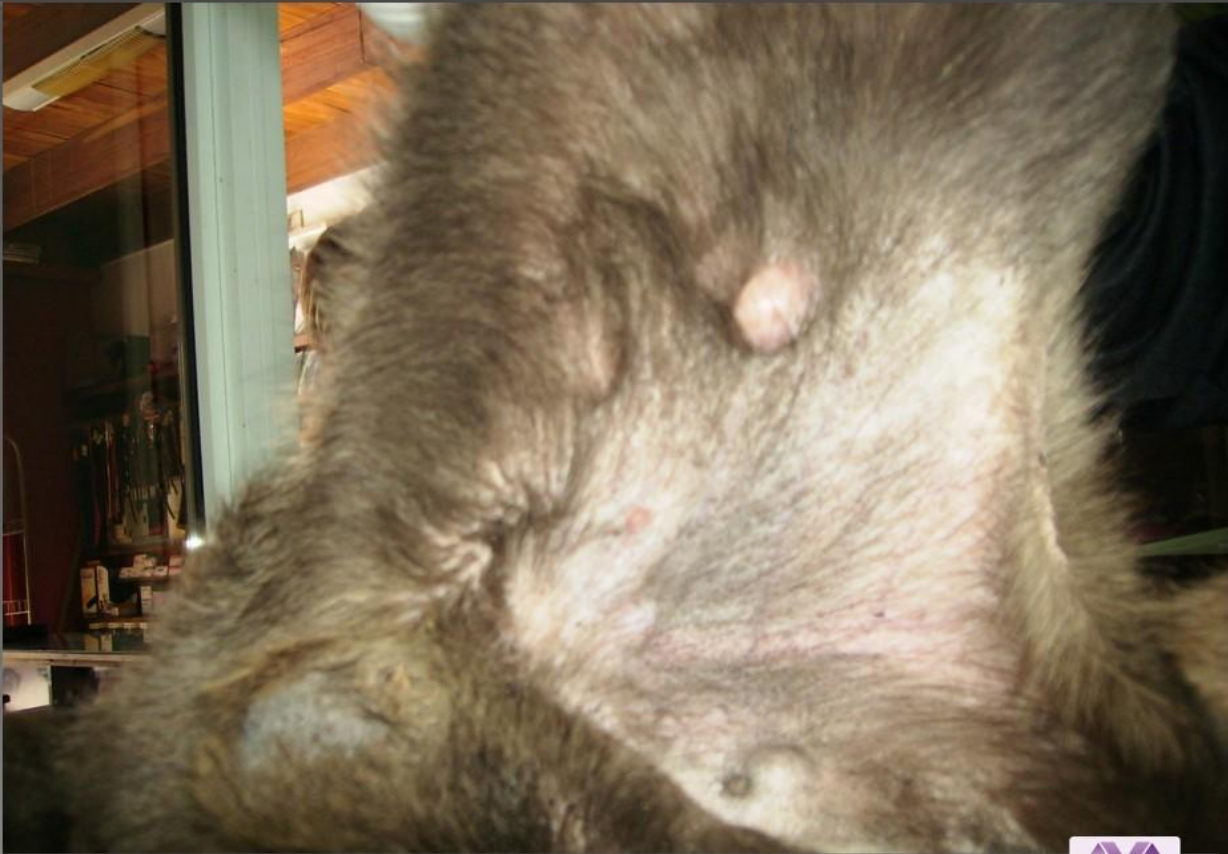

Tumor venéreo transmisible

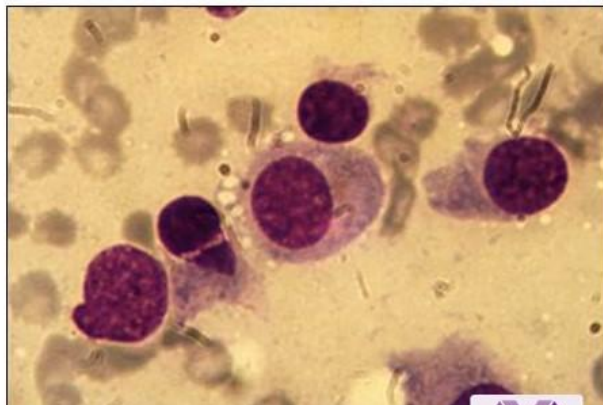
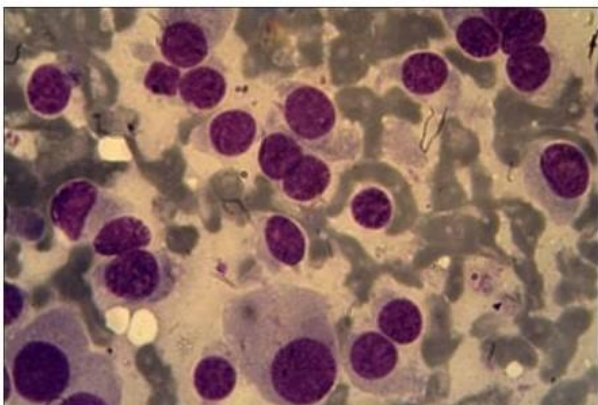
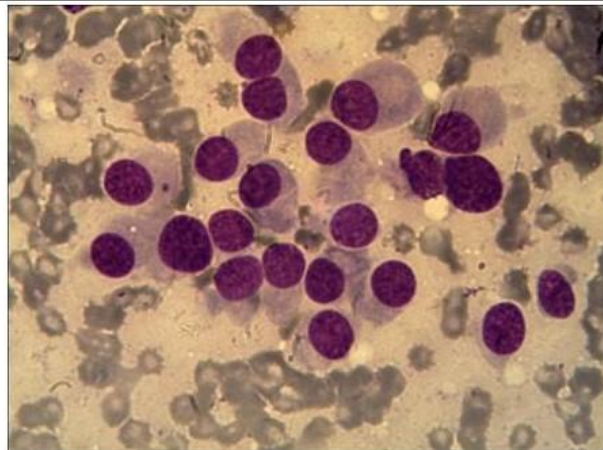
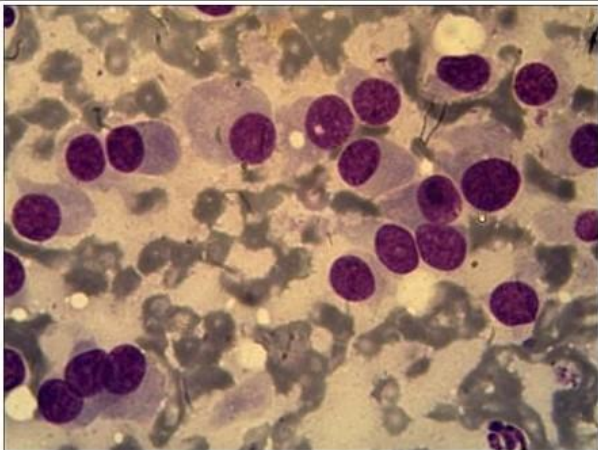


Tumor venéreo transmisible



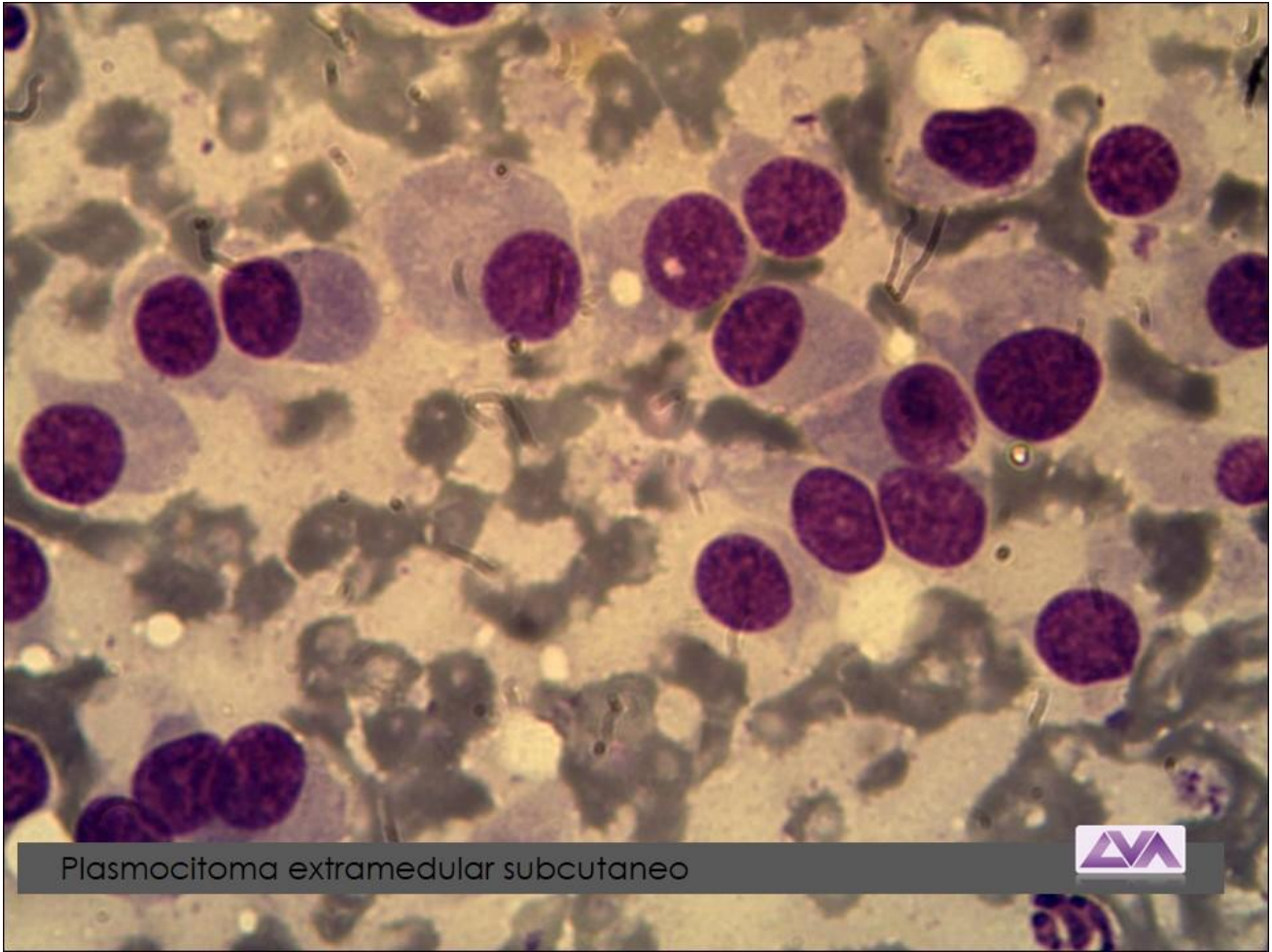


Tumor venéreo transmisible

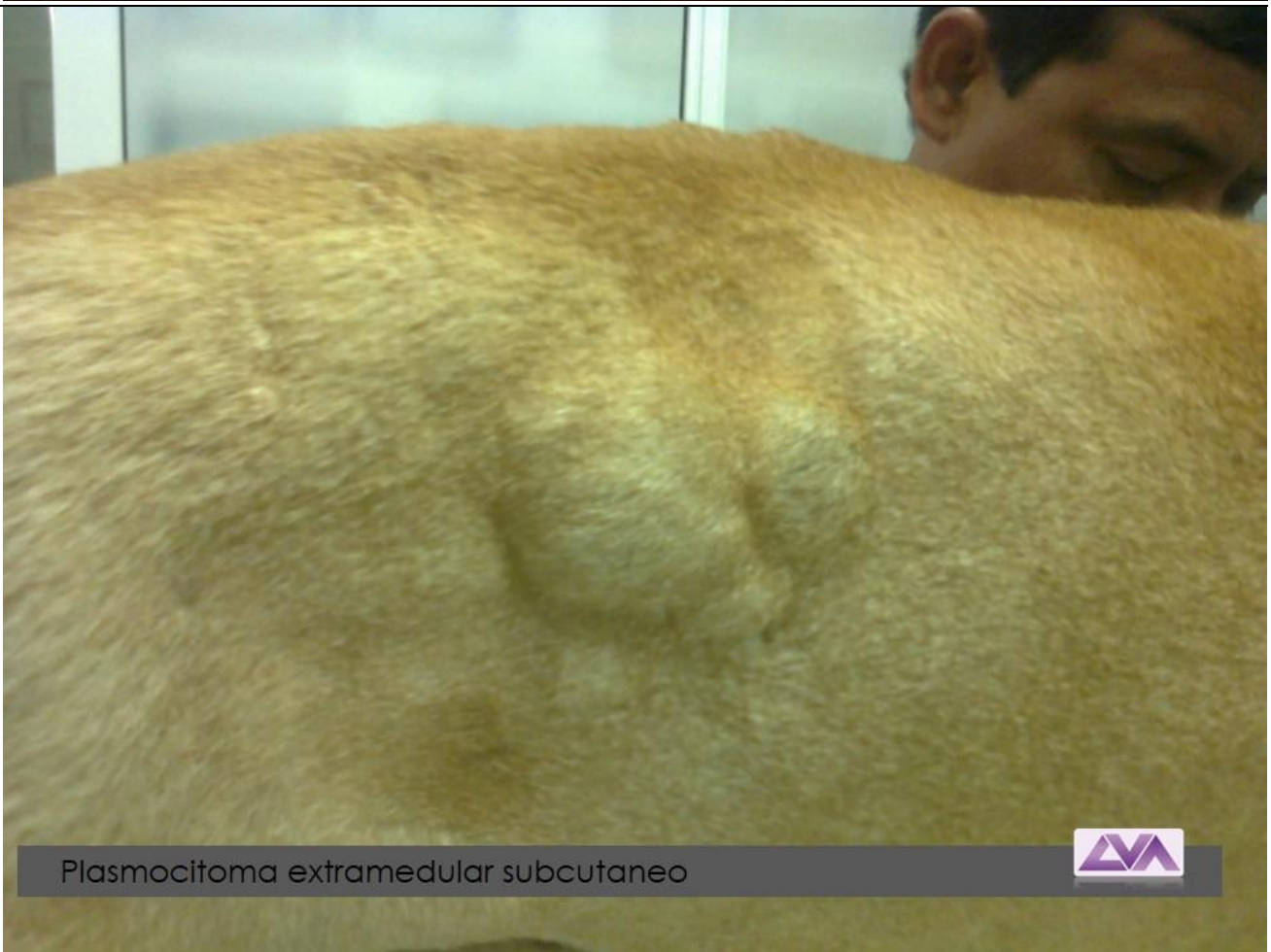

Plasmocitoma maligno, subcutaneo






Plasmocitoma extramedular subcutaneo

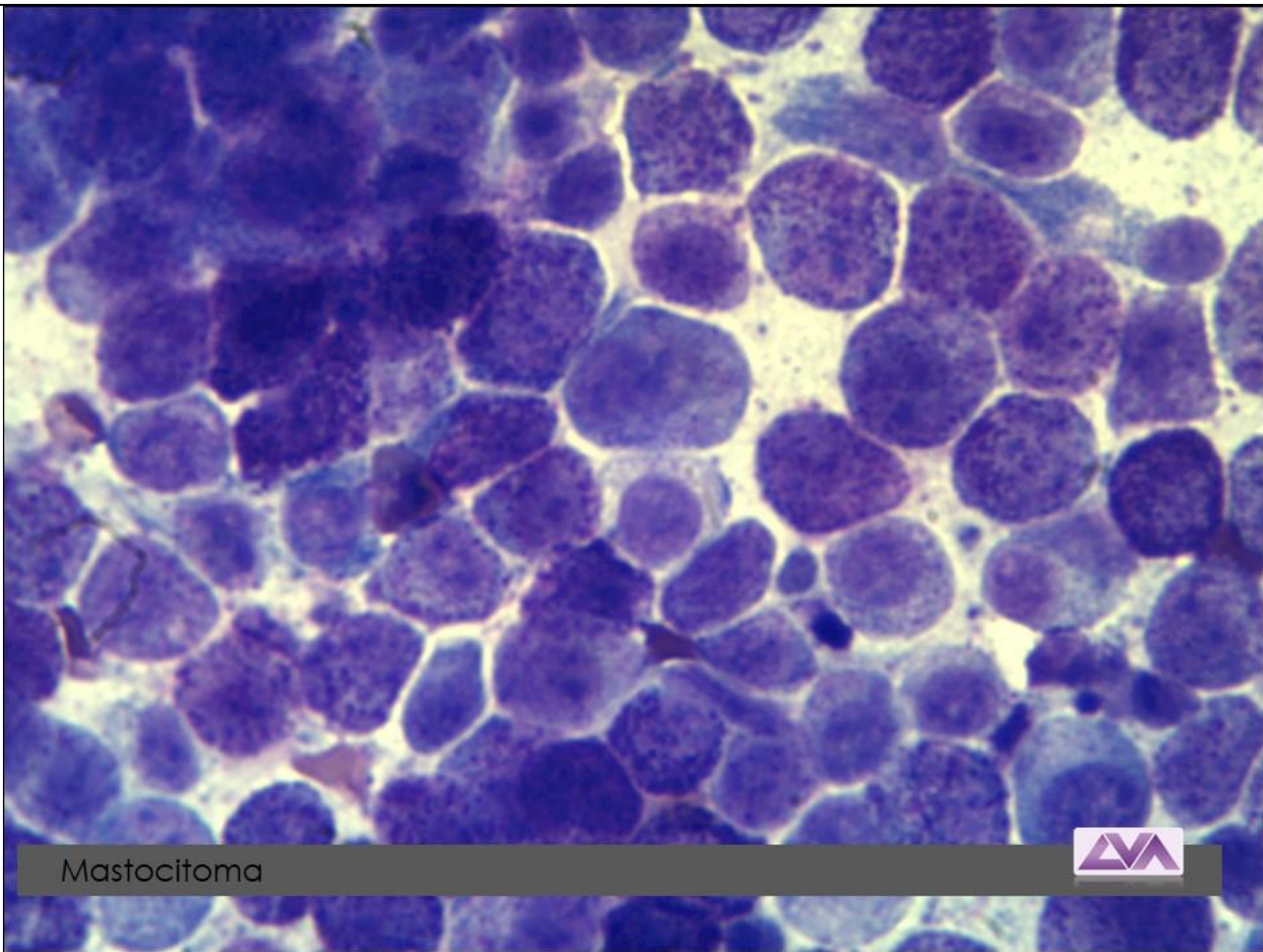


Plasmocitoma extramedular subcutaneo



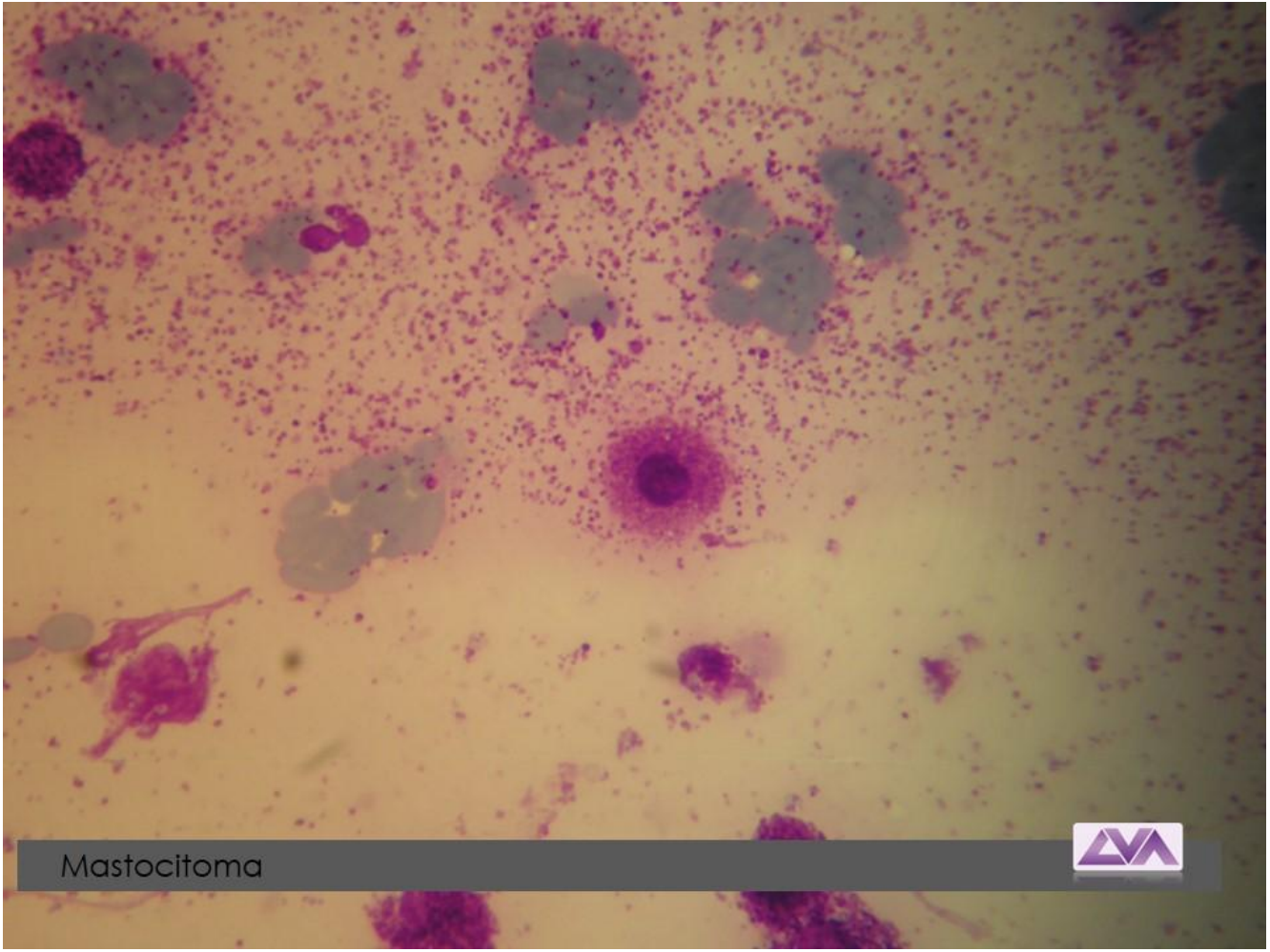


Plasmocitoma extramedular



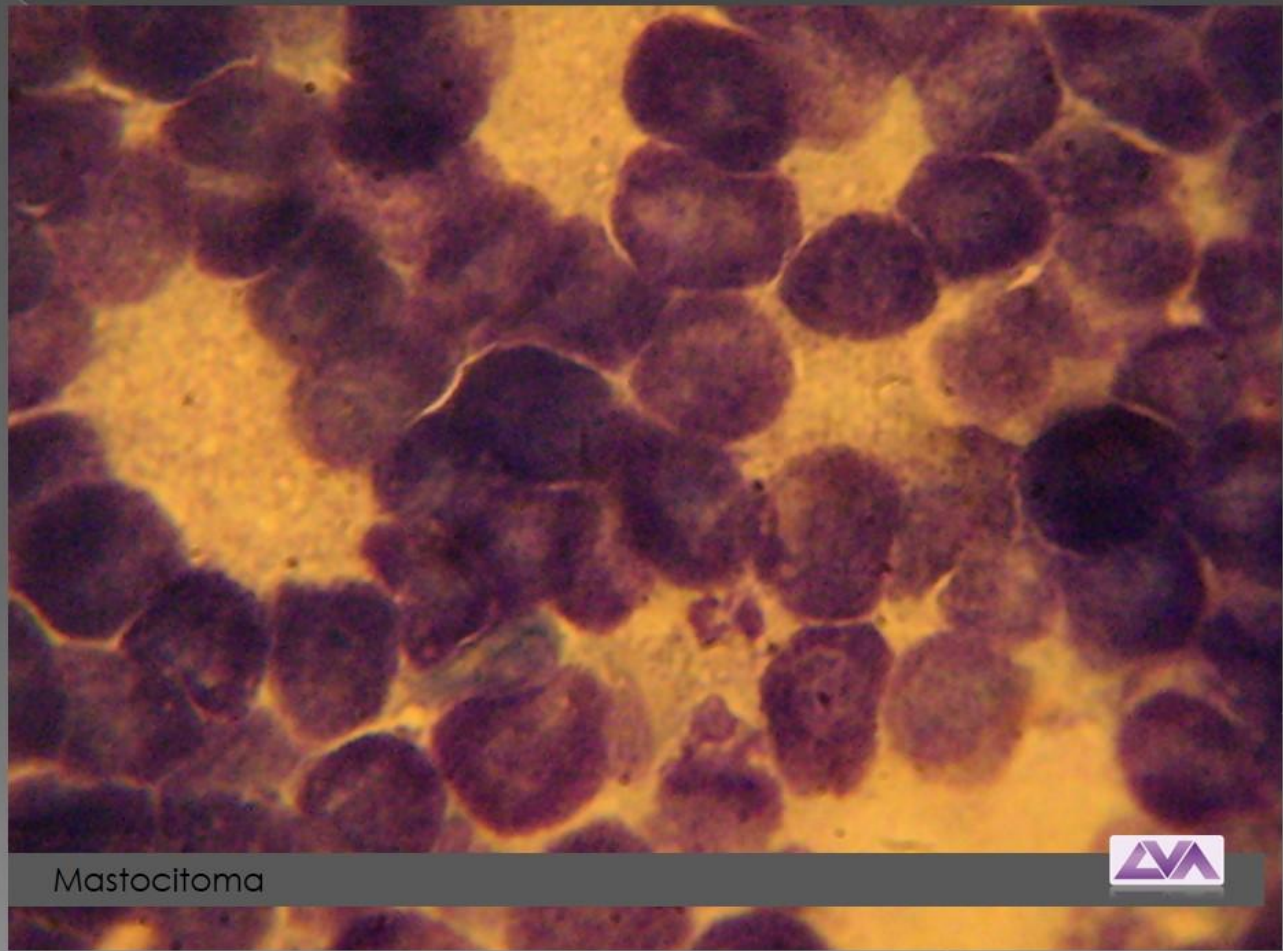
Mastocitoma



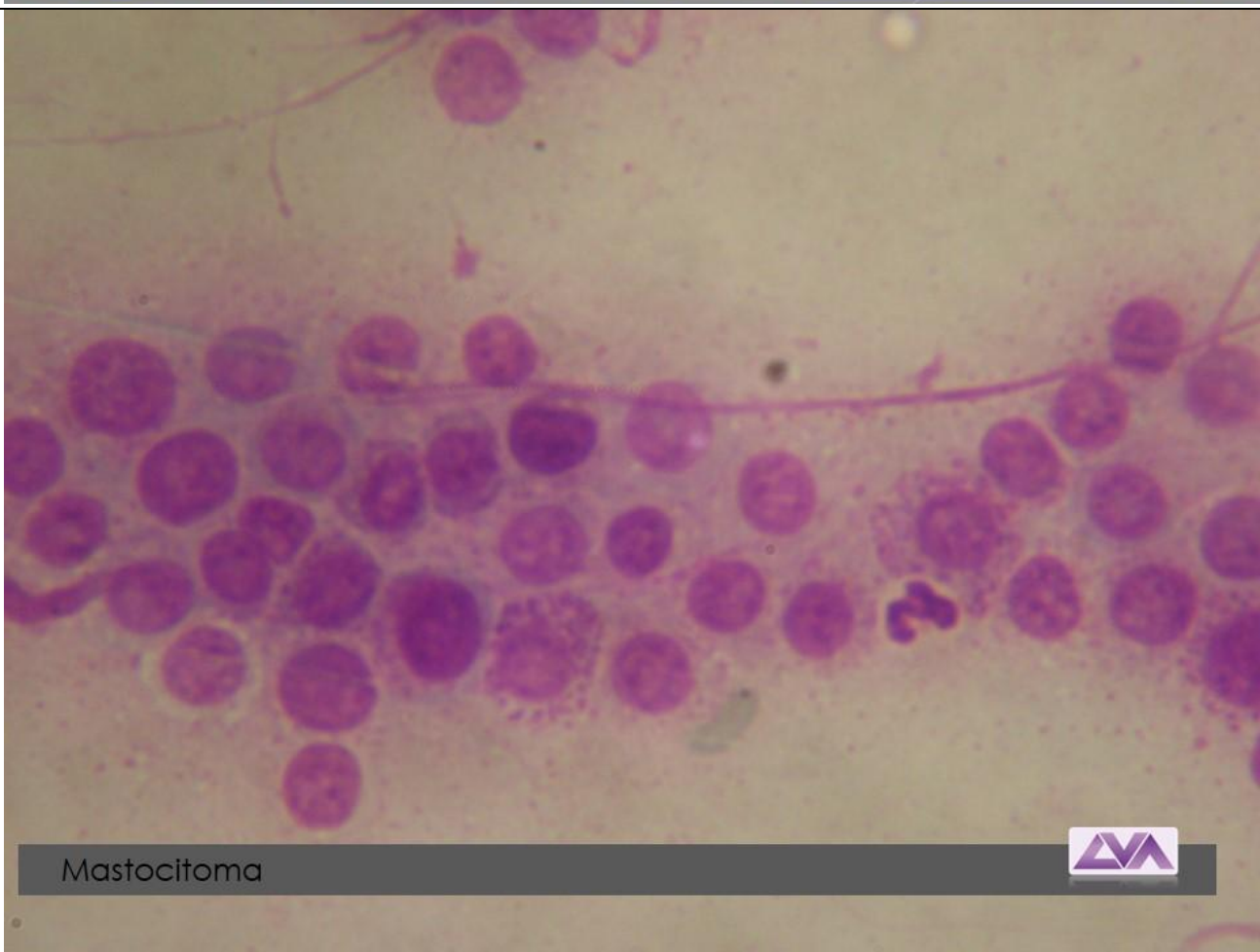

Mastocitoma



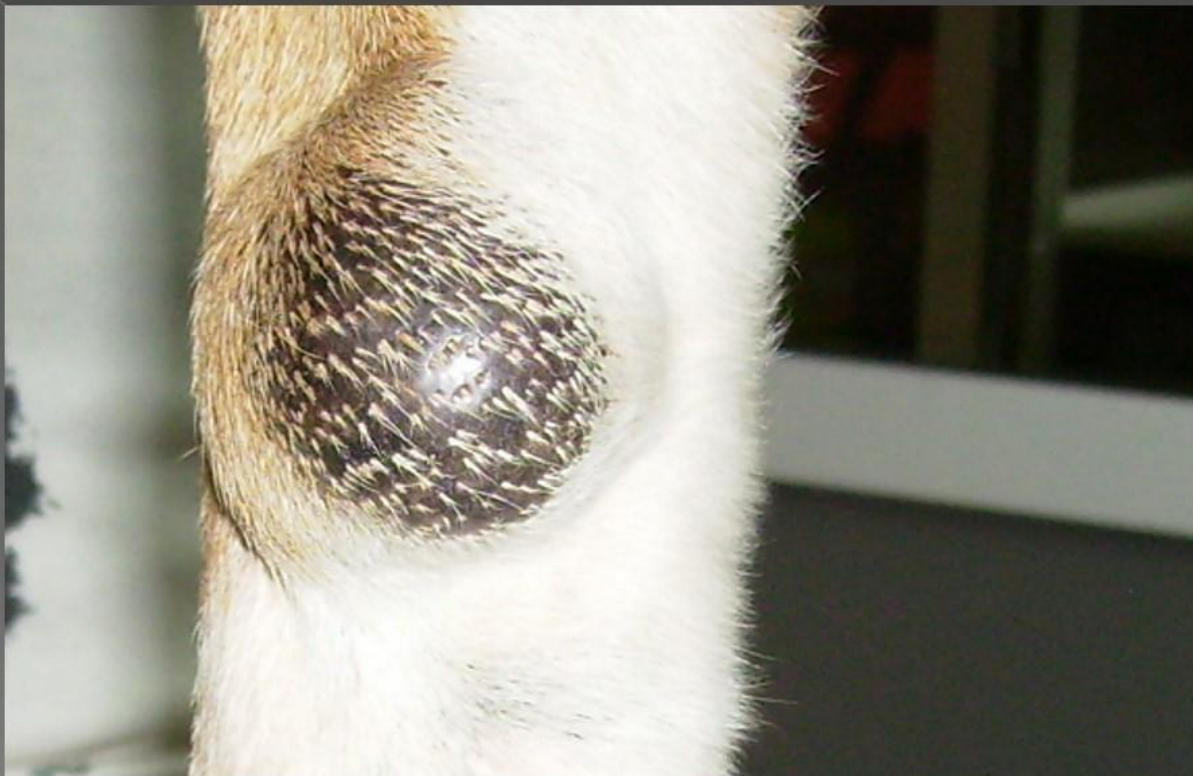

Mastocitoma

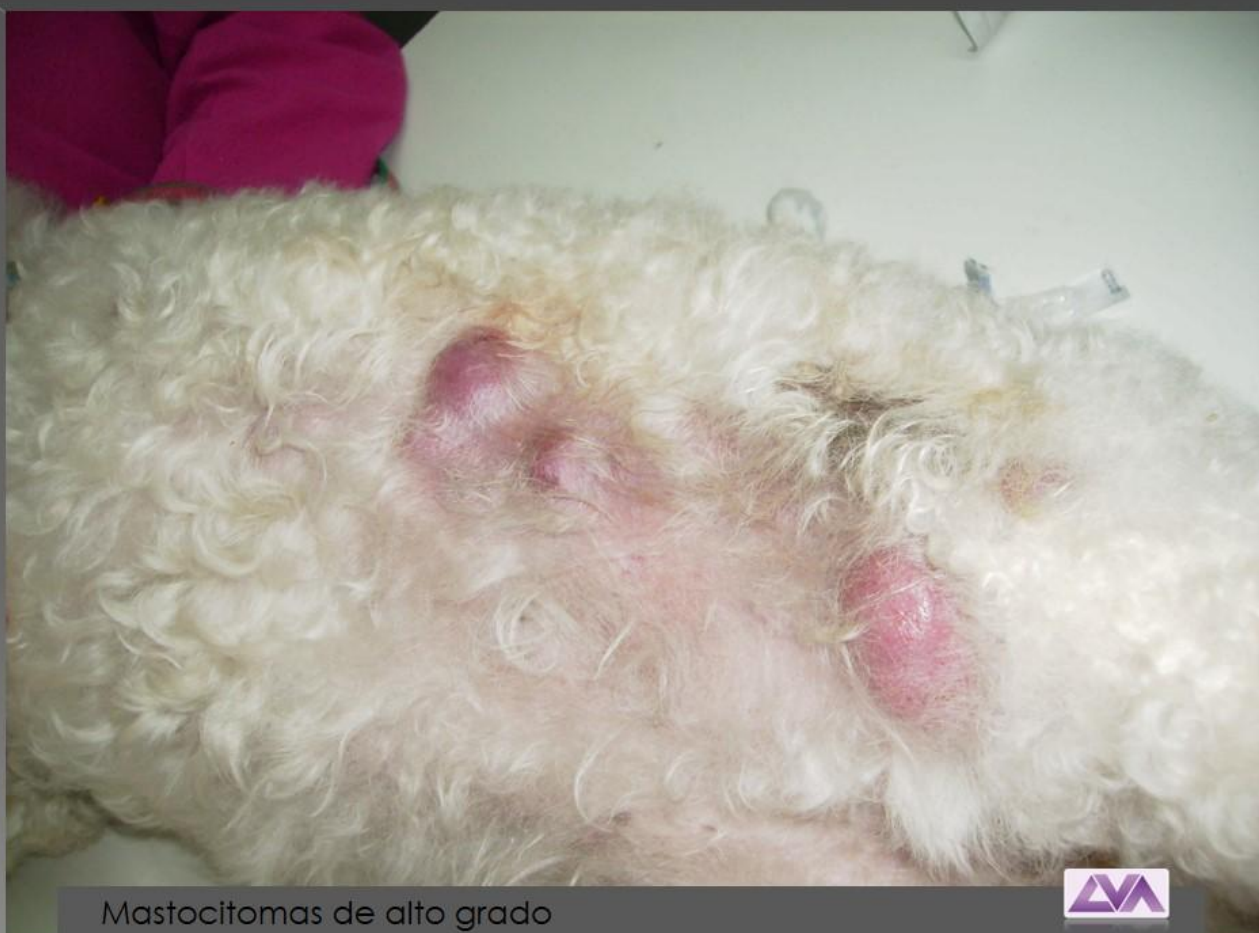

Mastocitoma



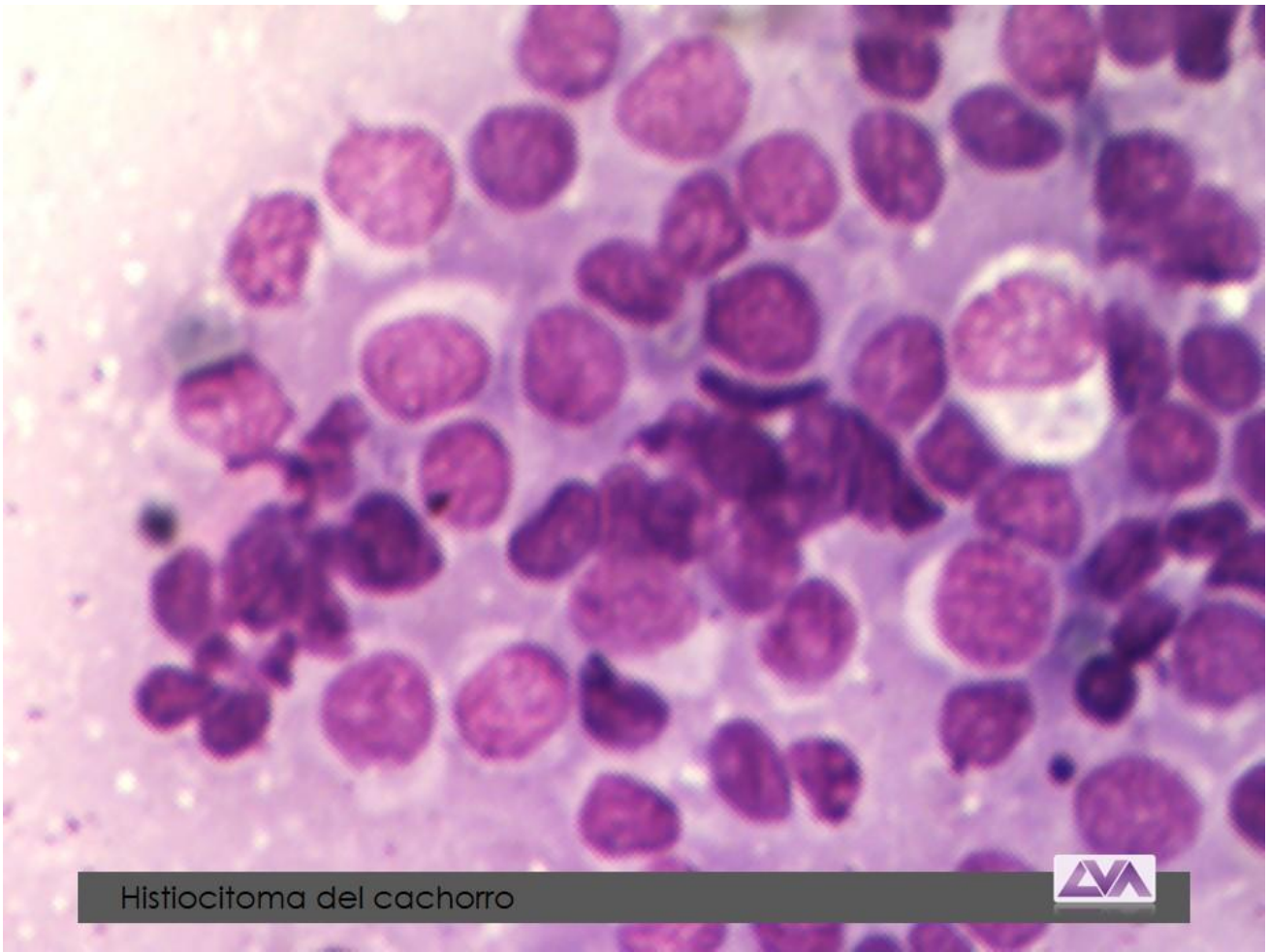

Mastocitoma de bajo grado

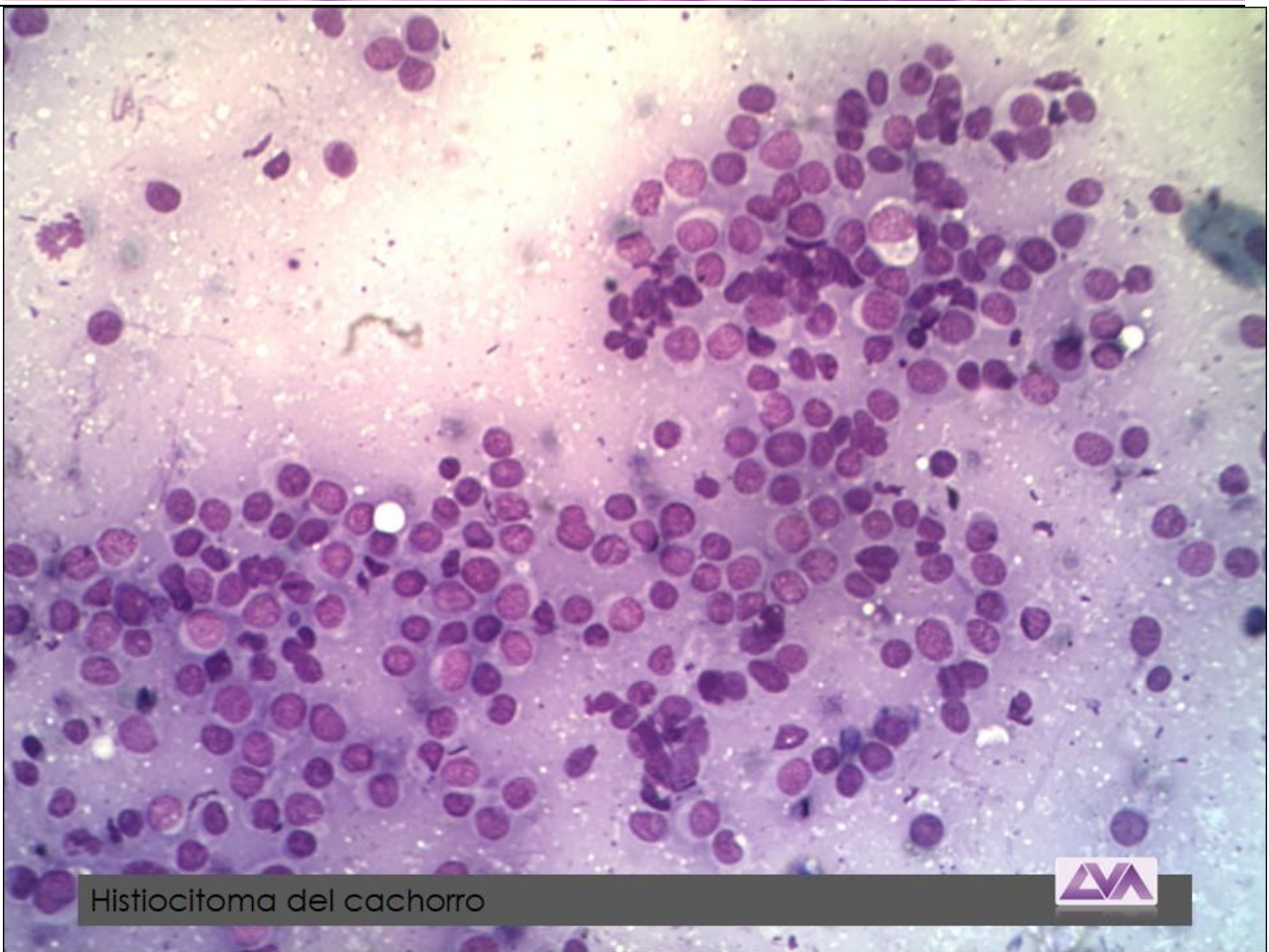


Mastocitomas de alto grado



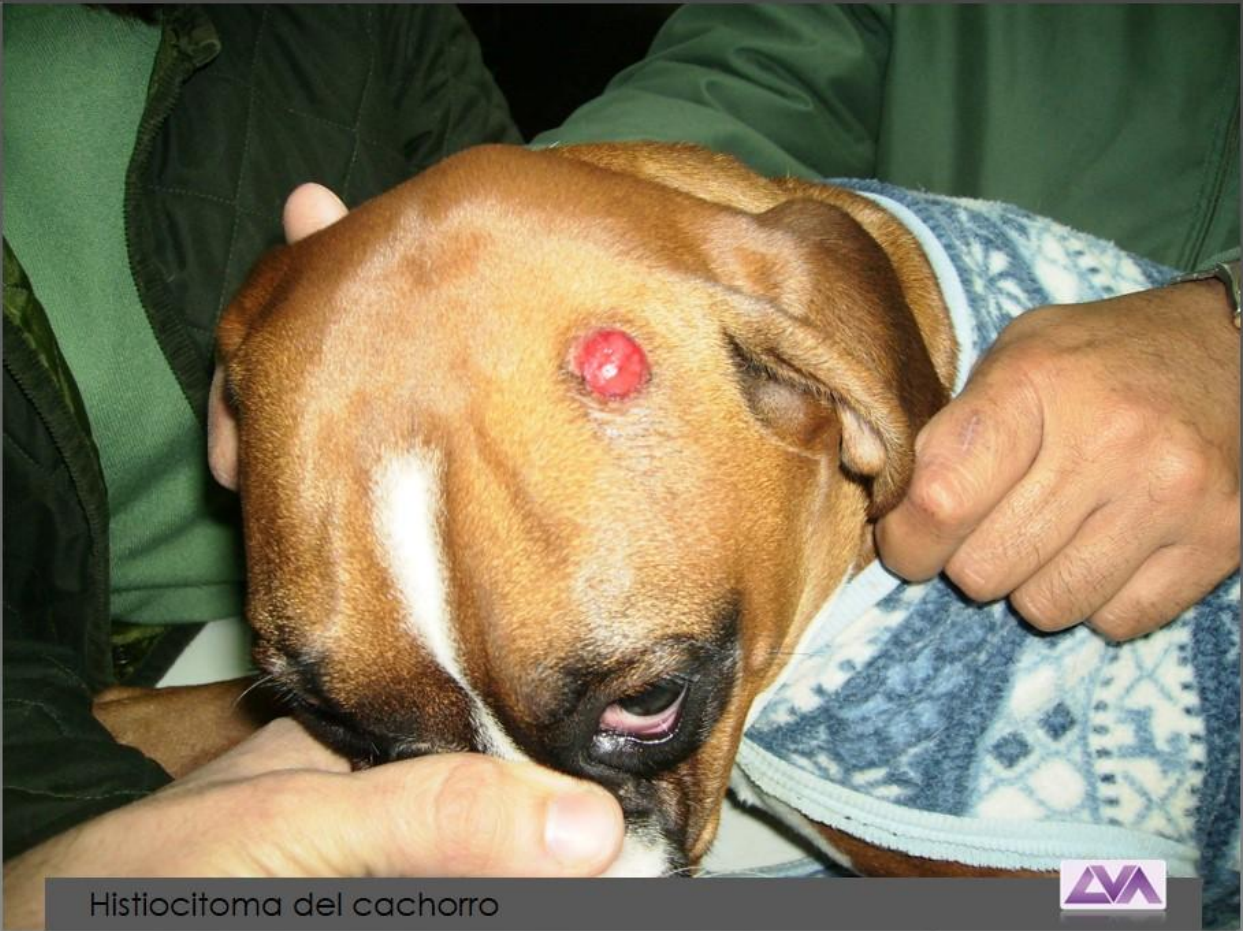

Histiocitoma del cachorro

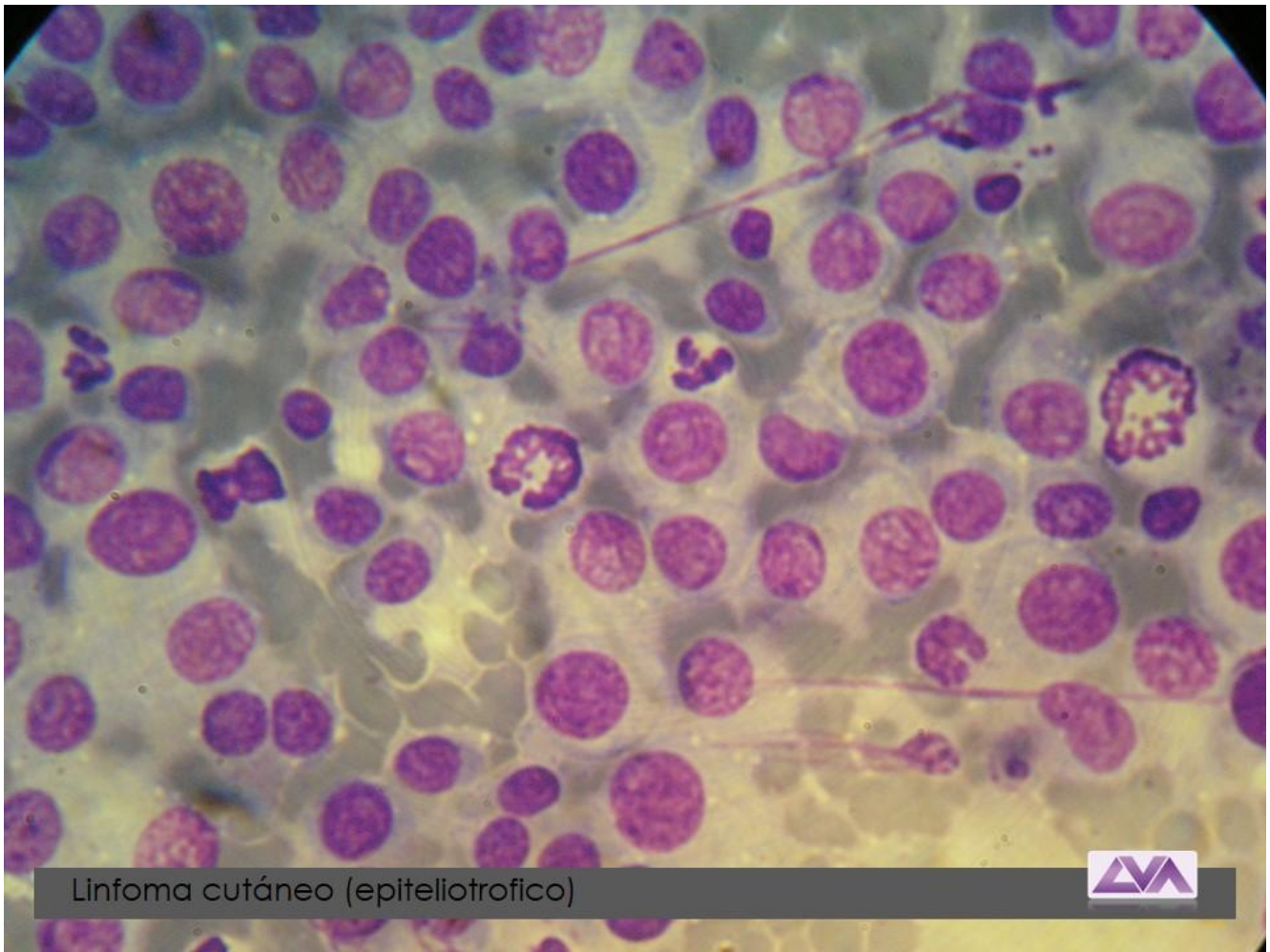


Histiocitoma del cachorro



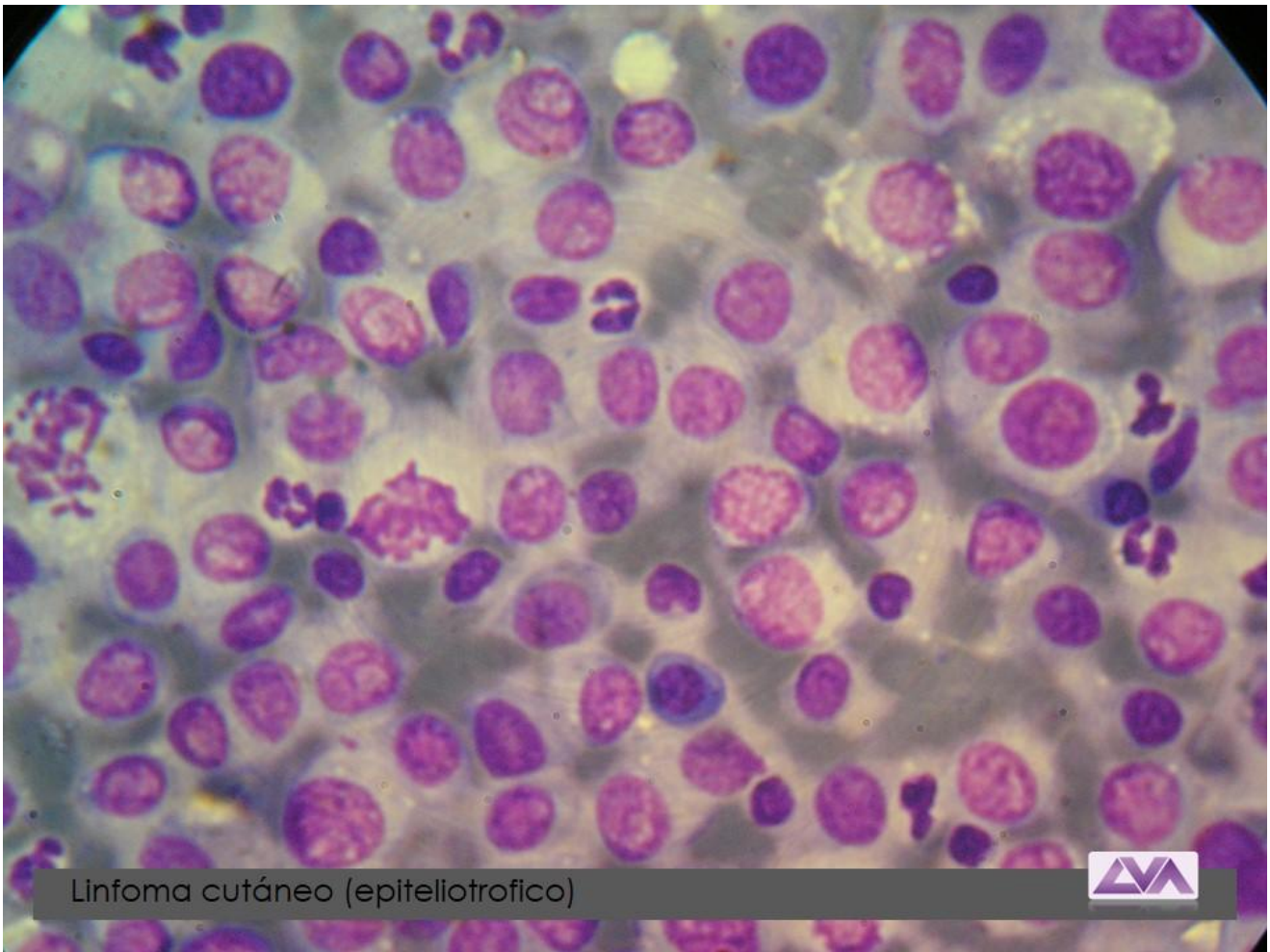


Histiocitoma del cachorro

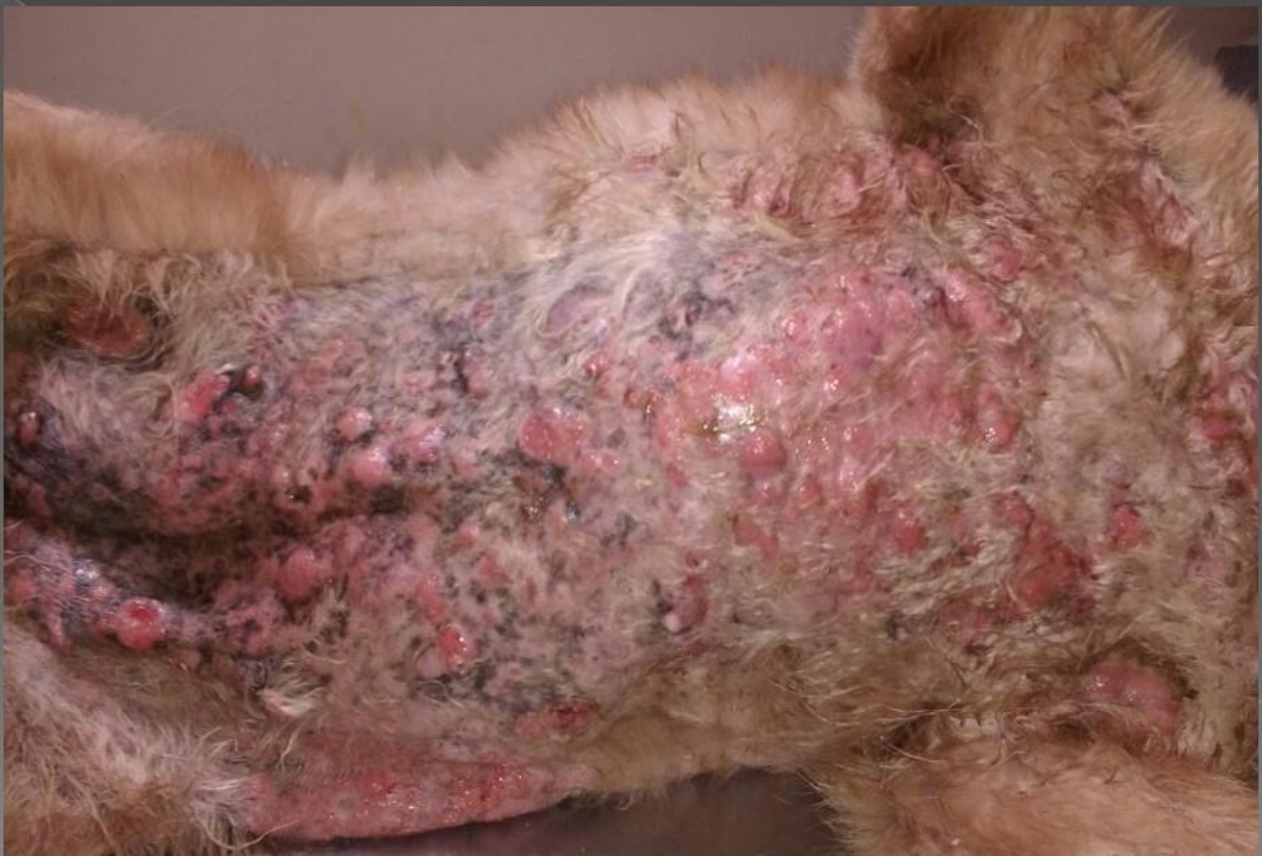

Linfoma cutáneo (epiteliotrófico)



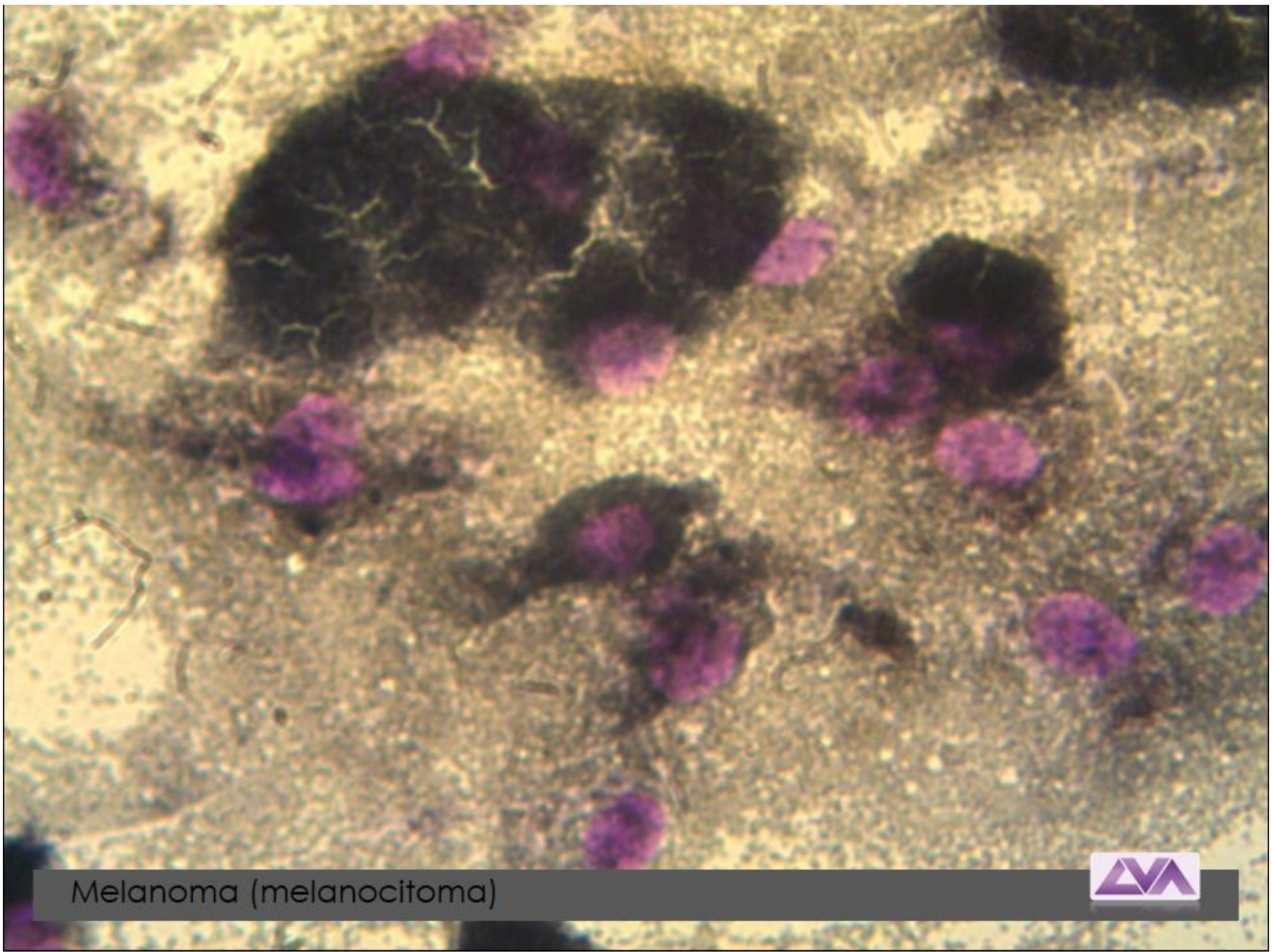


Linfoma cutáneo (epitellotrófico)

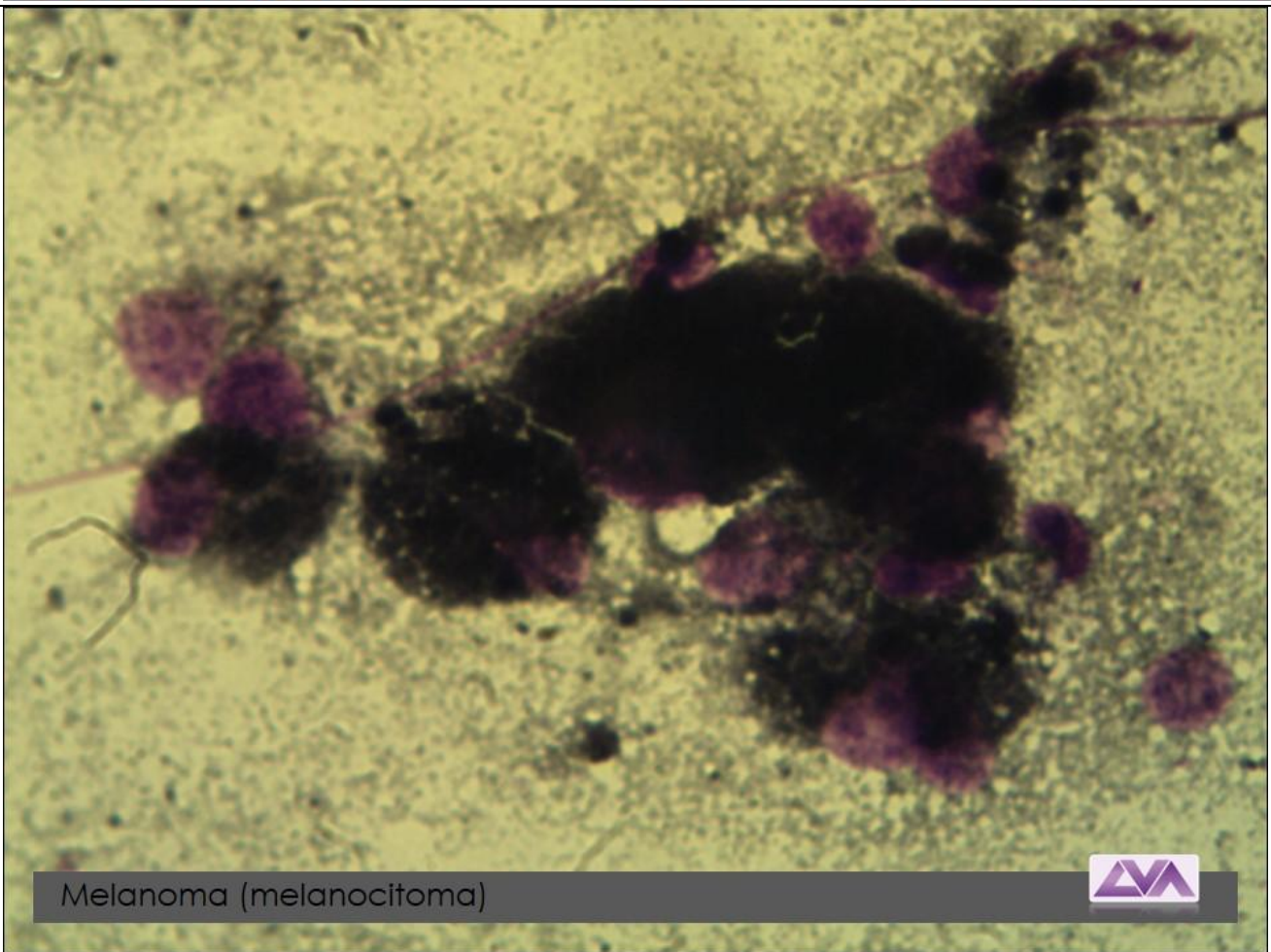


Linfoma cutáneo /foto: Dra. Laura Elias



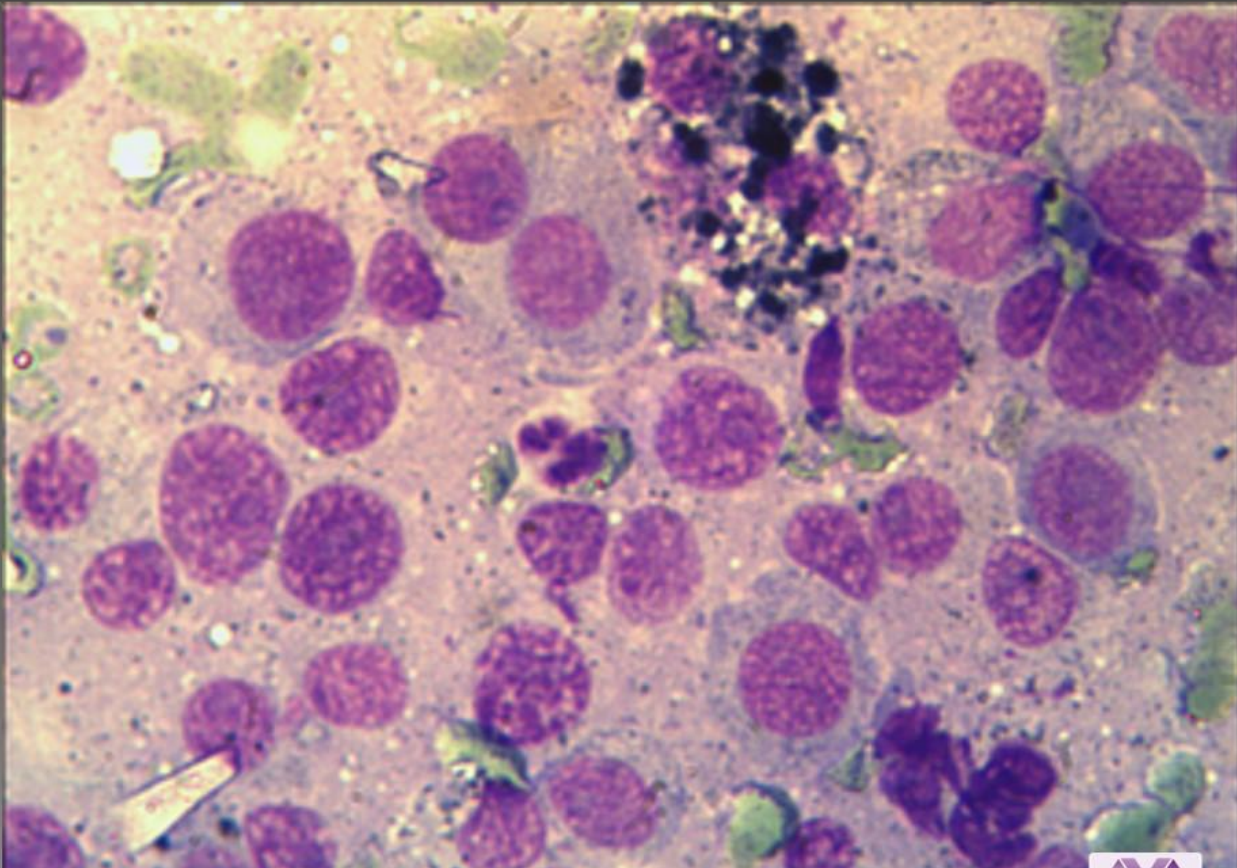


Melanoma (melanocitoma)



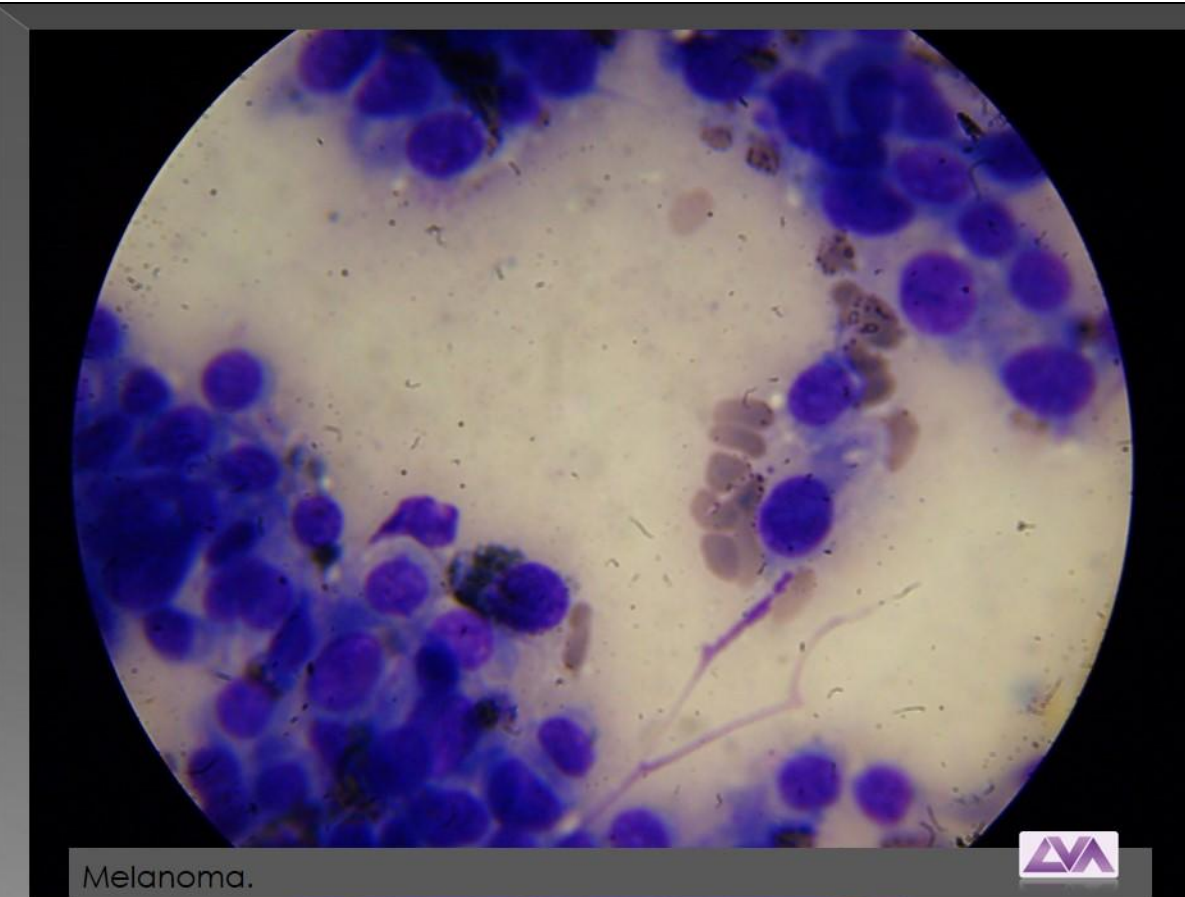
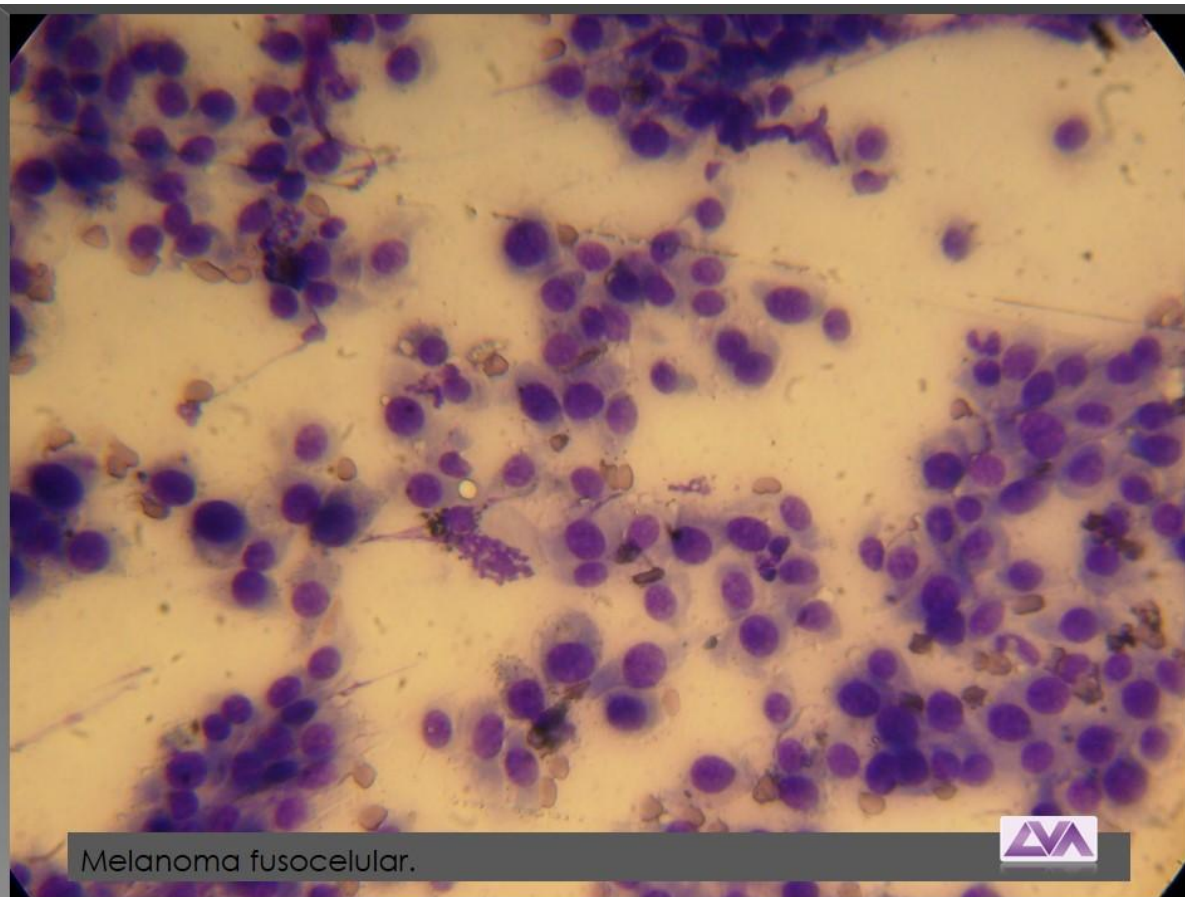
Melanoma (melanocitoma)

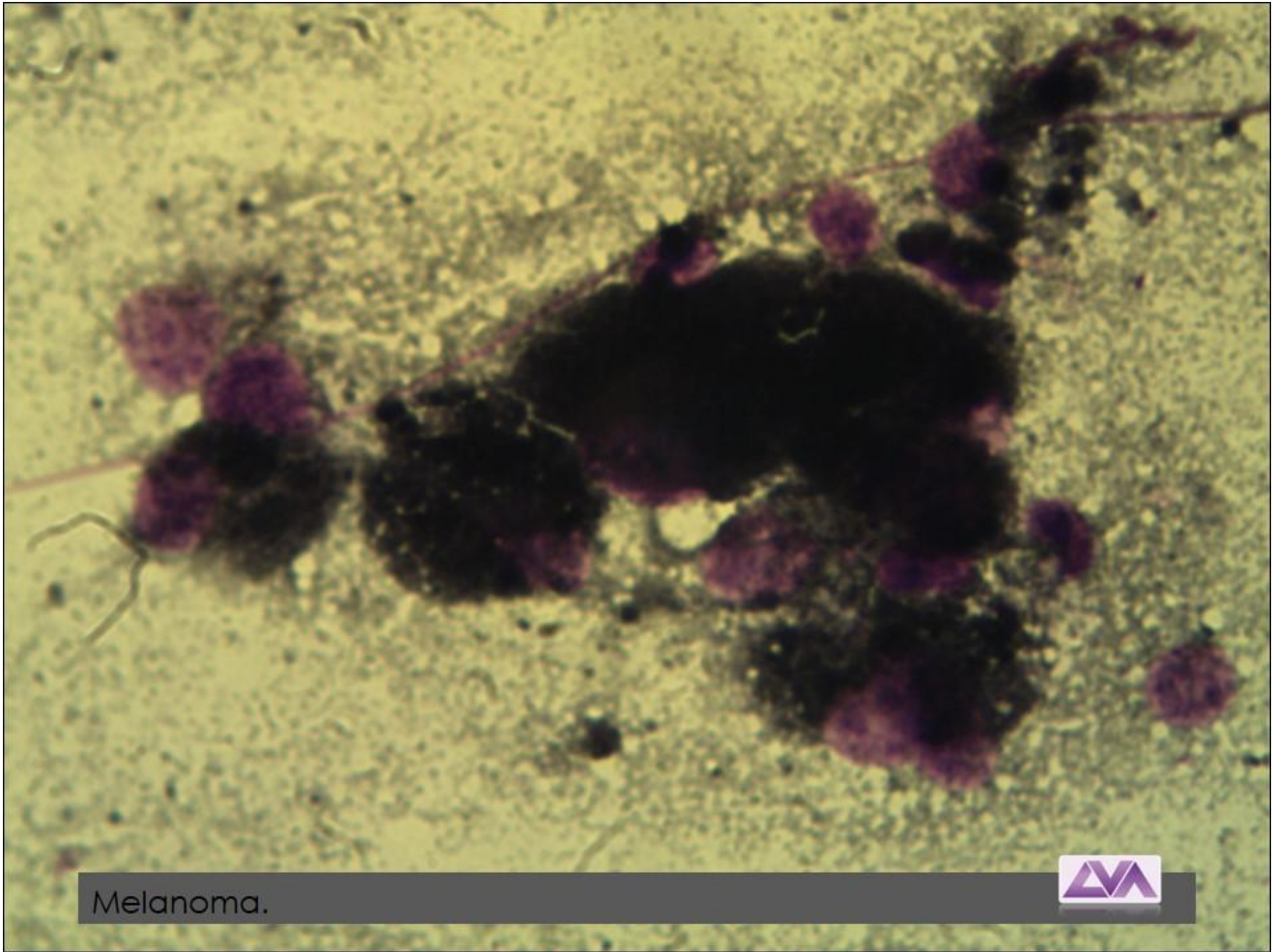




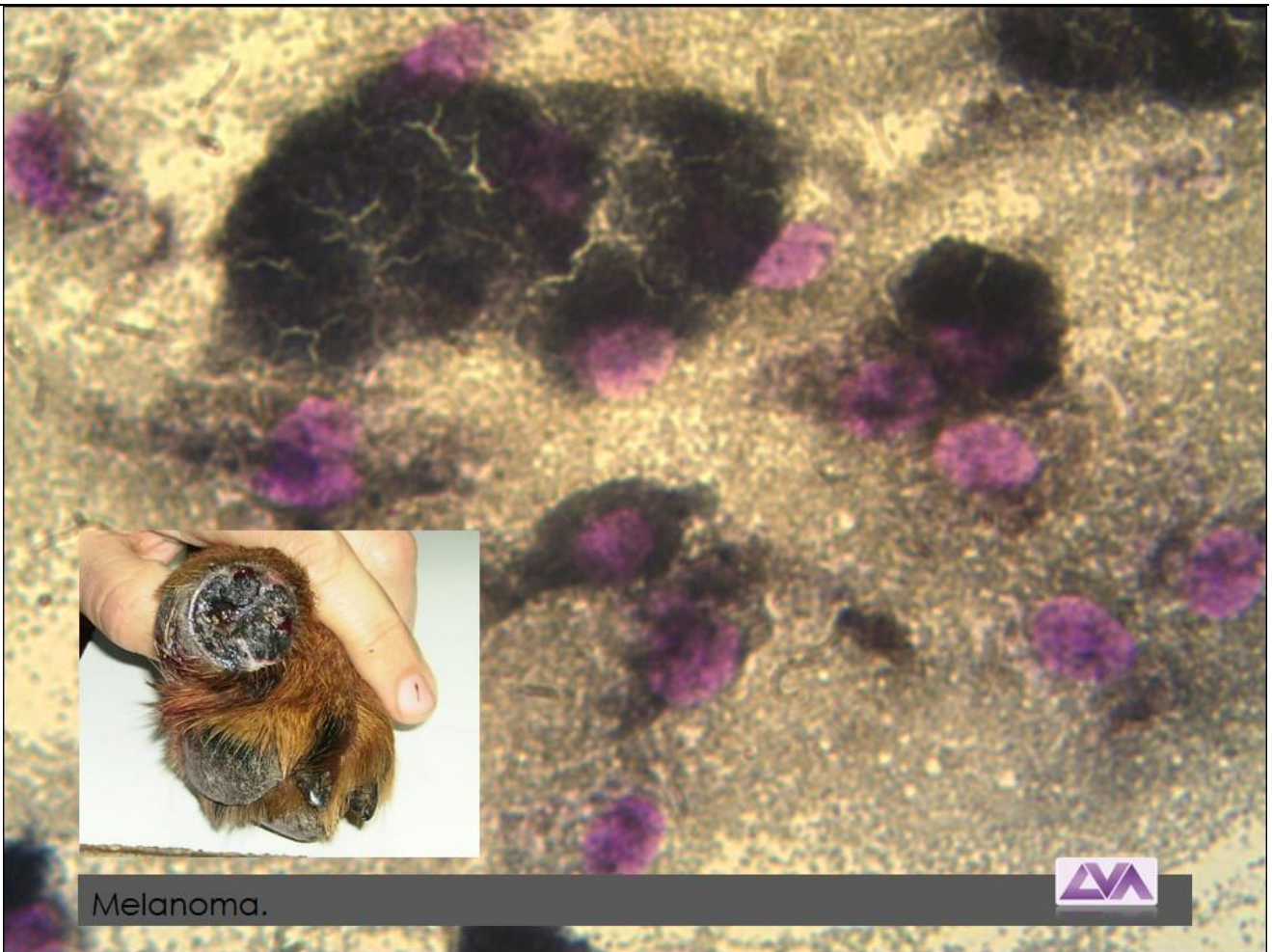
Melanoma maligno





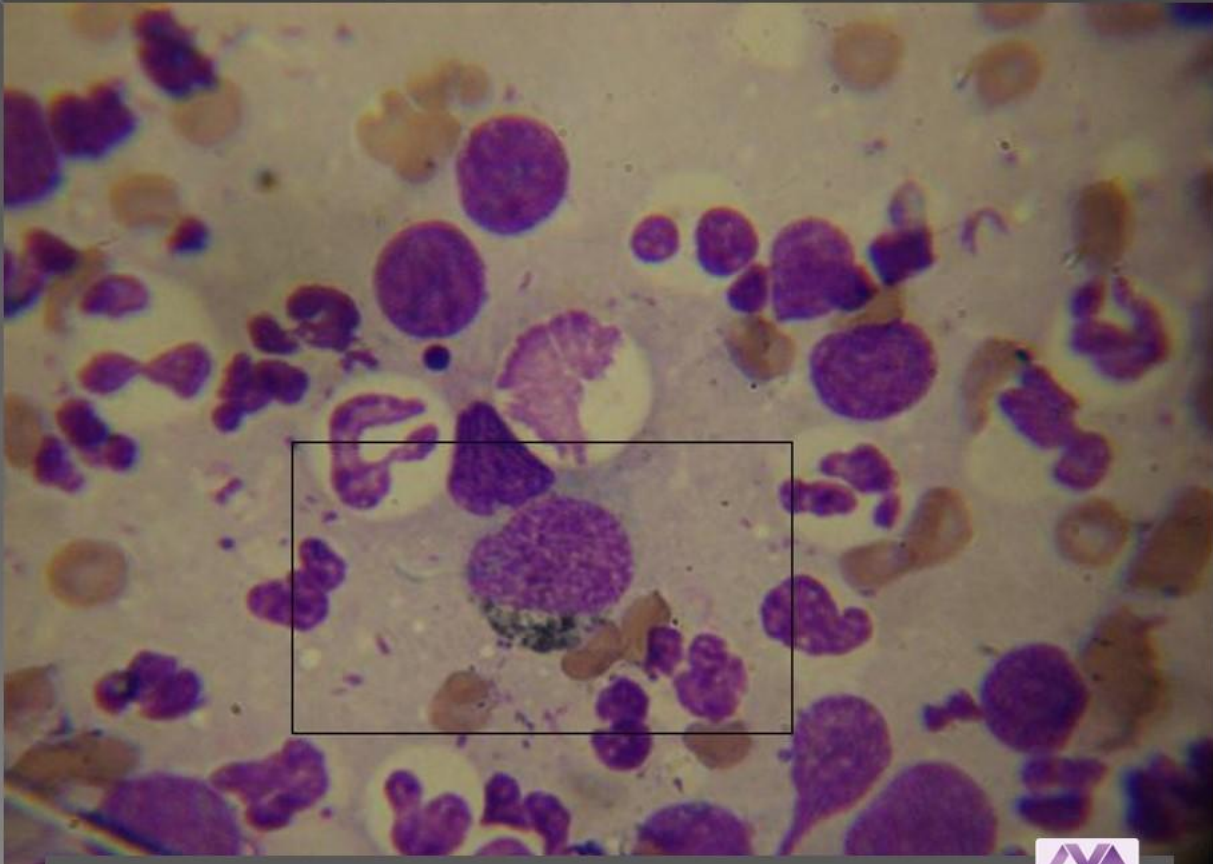


Melanoma.

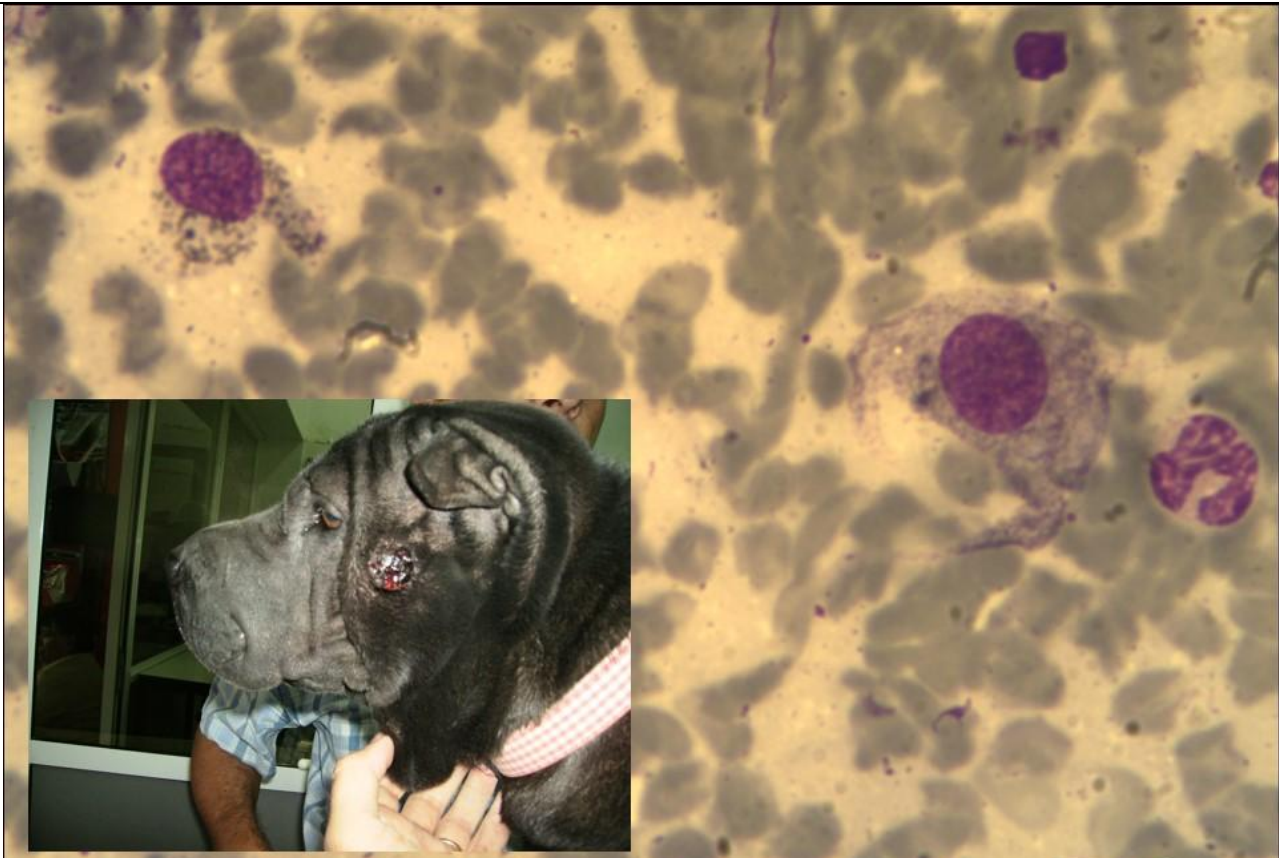


Melanoma.



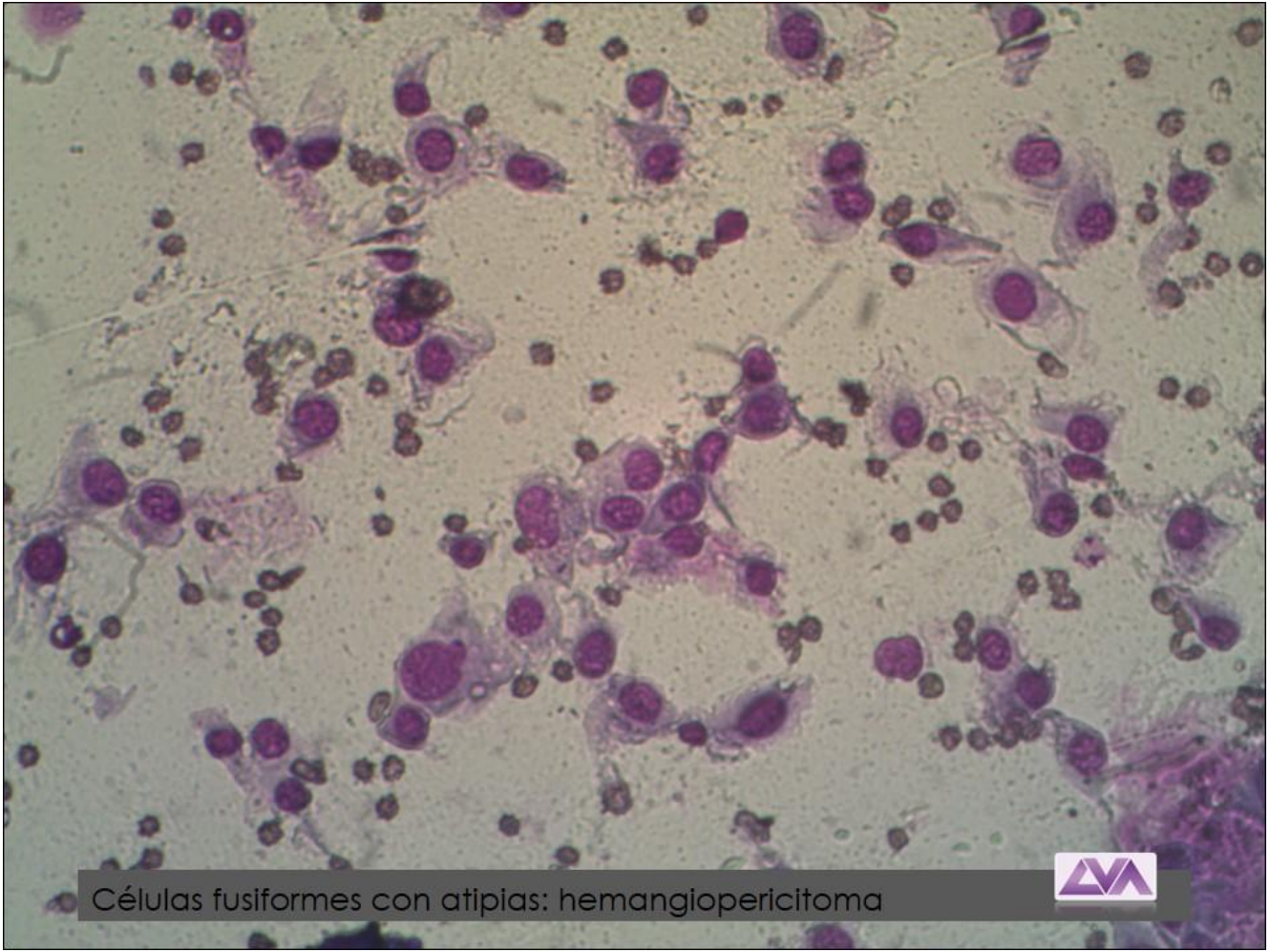


Melanoma.



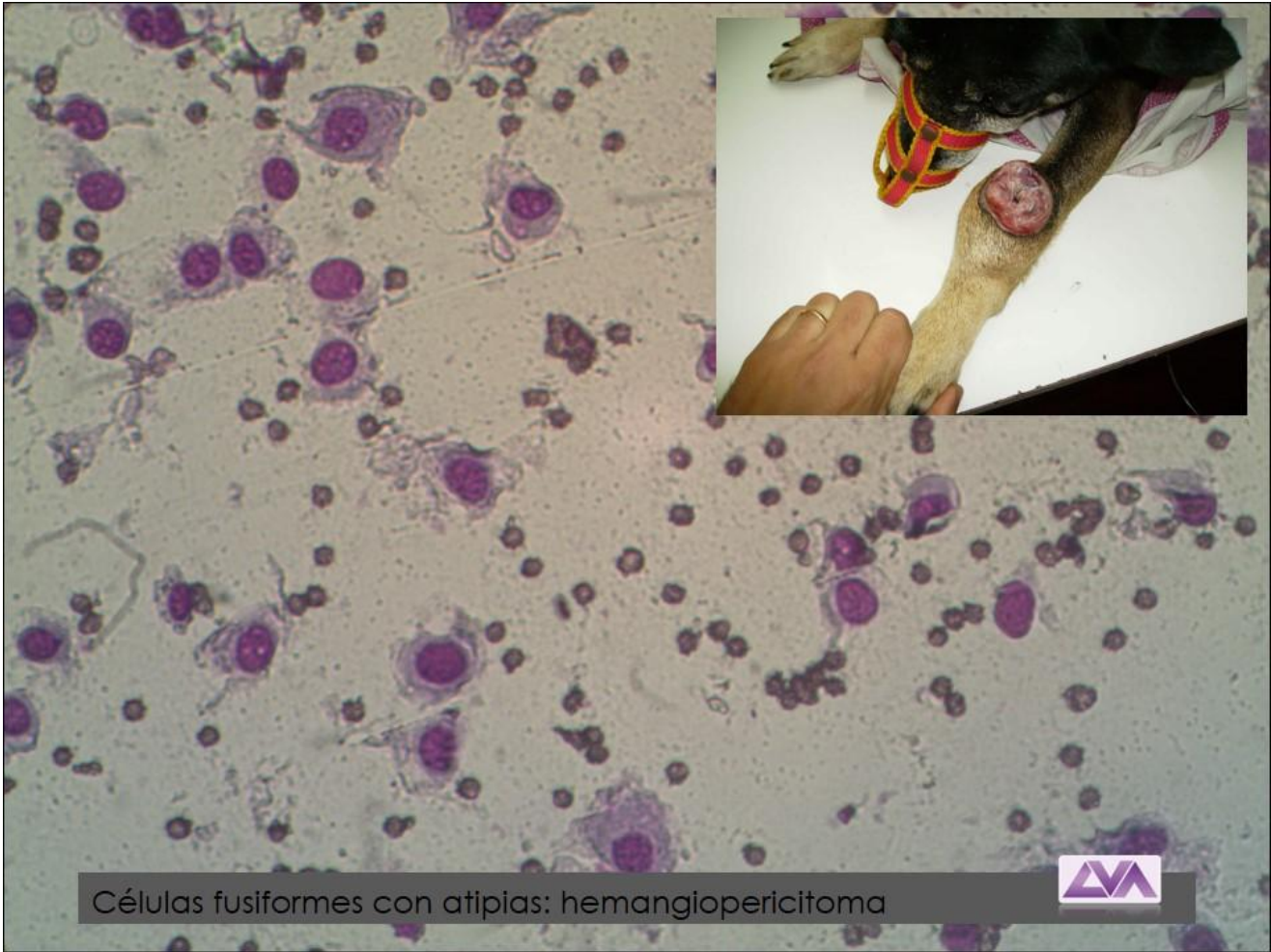
Melanoma.



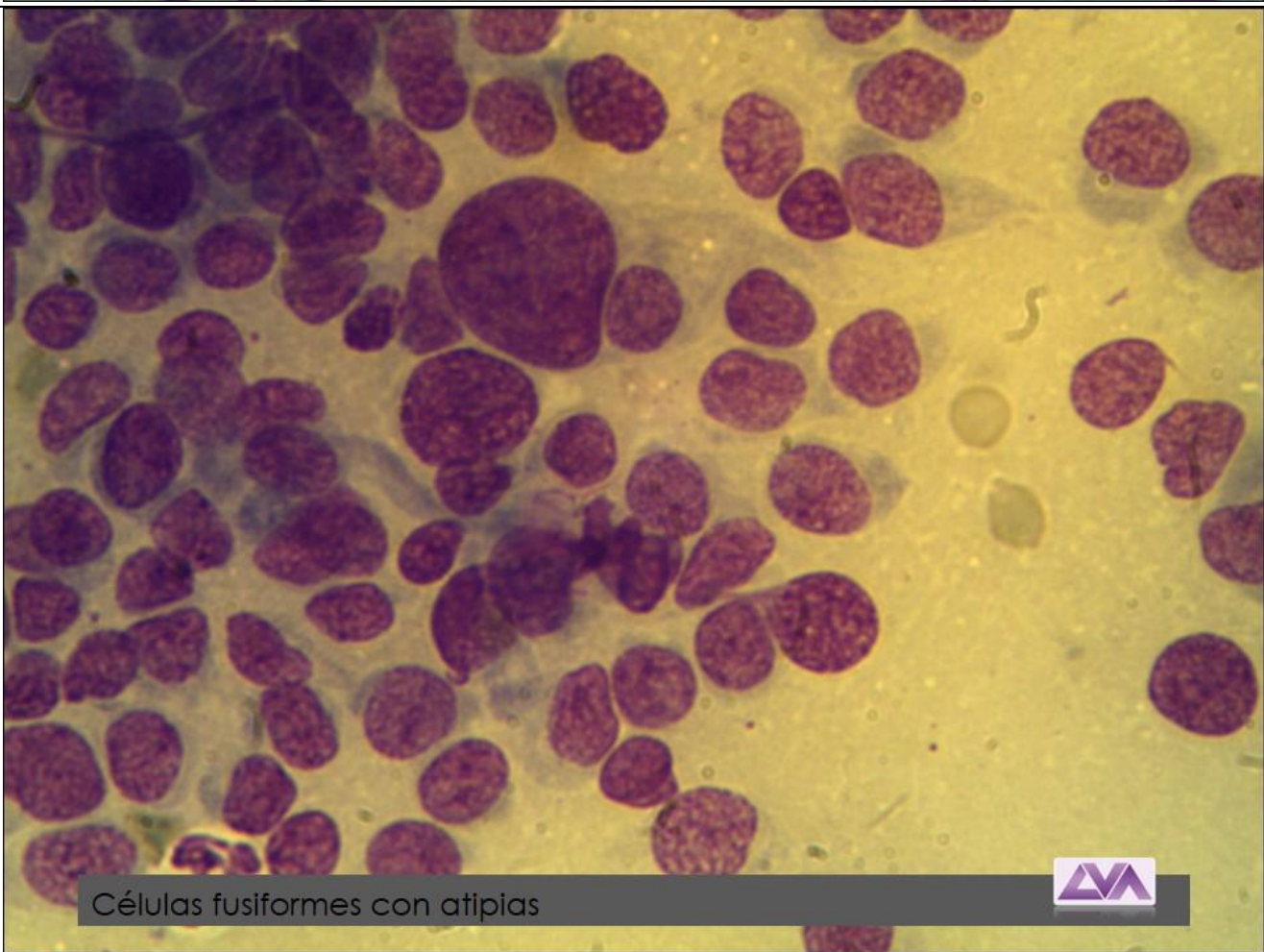


Células fusiformes con atipias: hemangiopericitoma

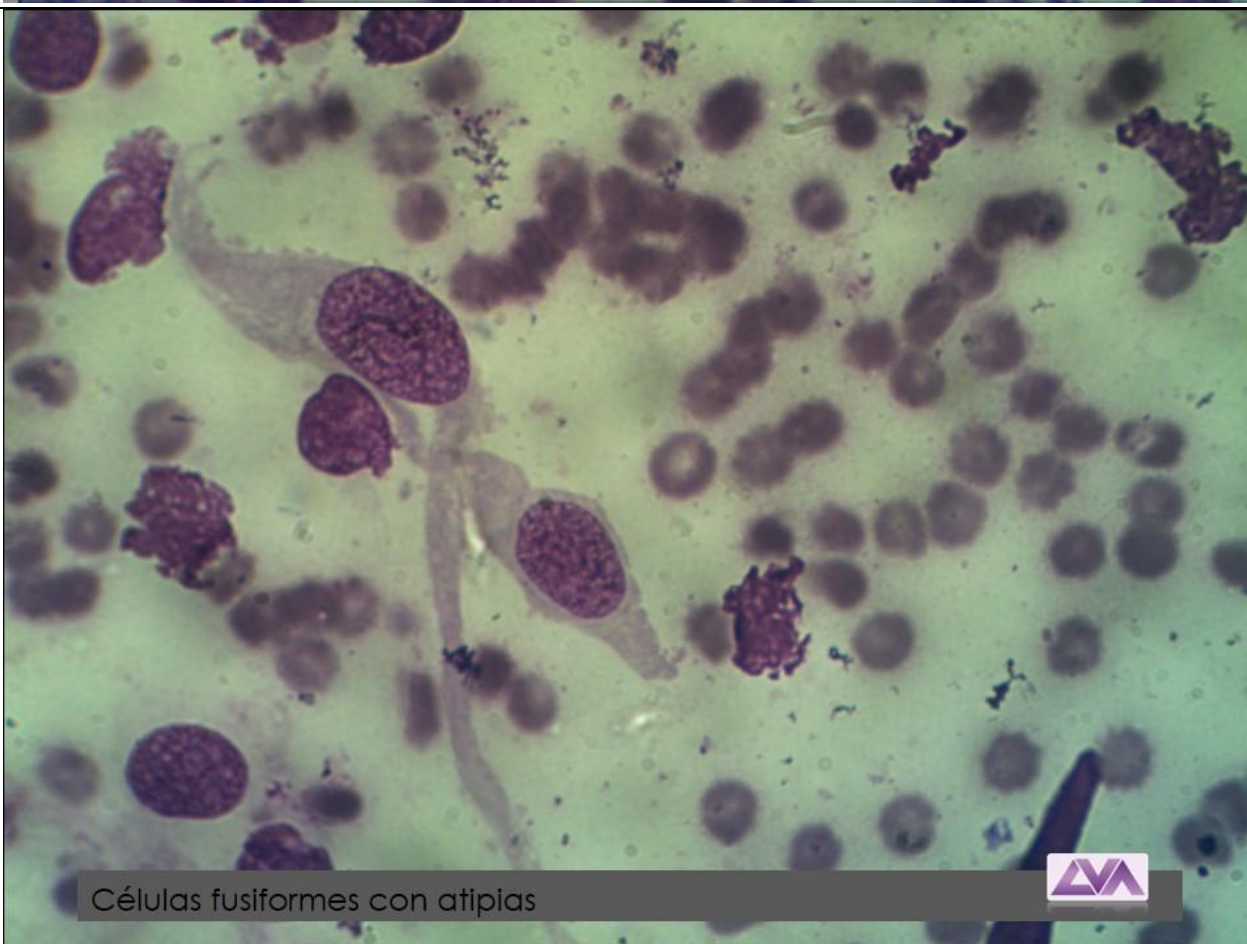
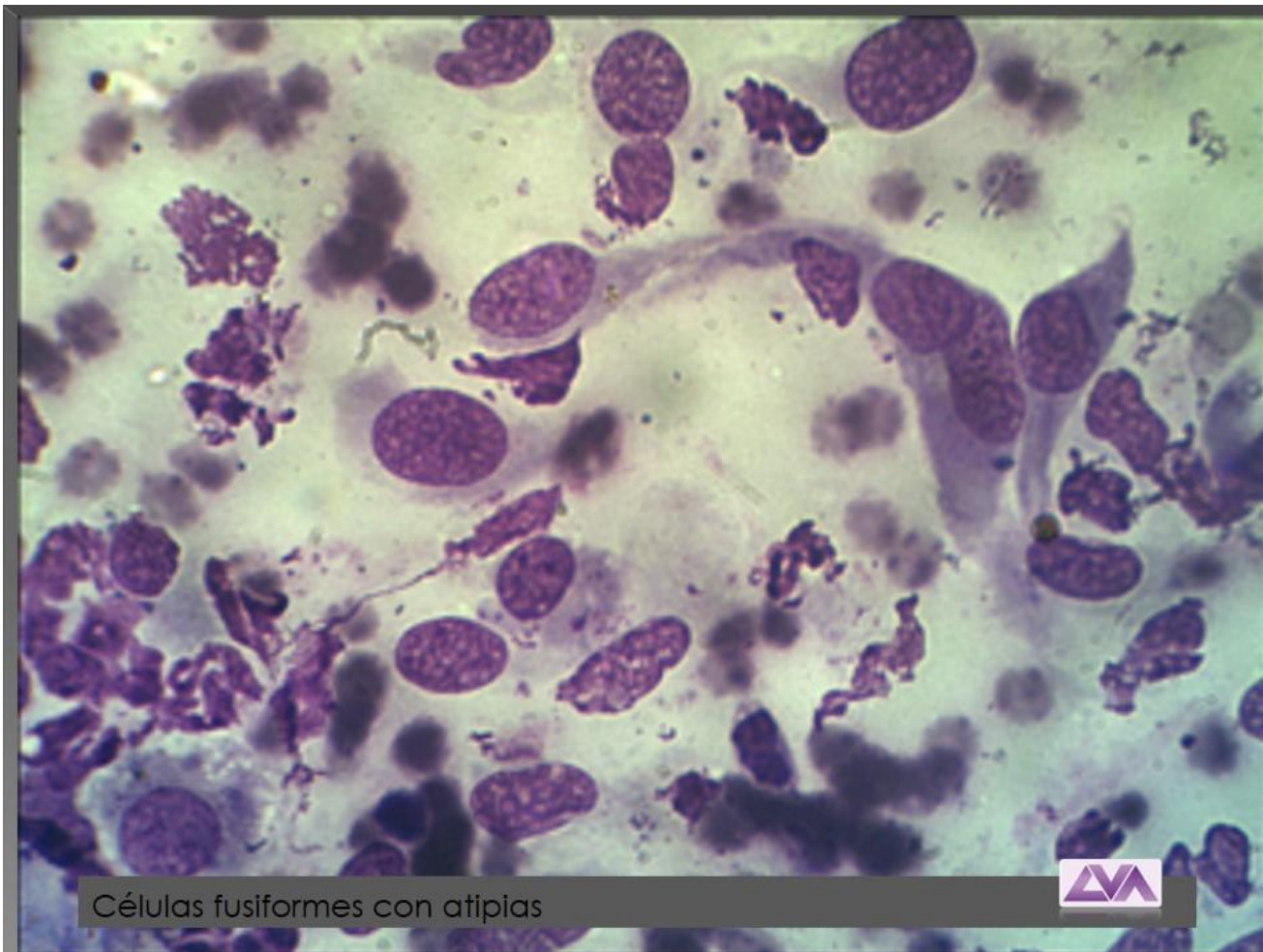


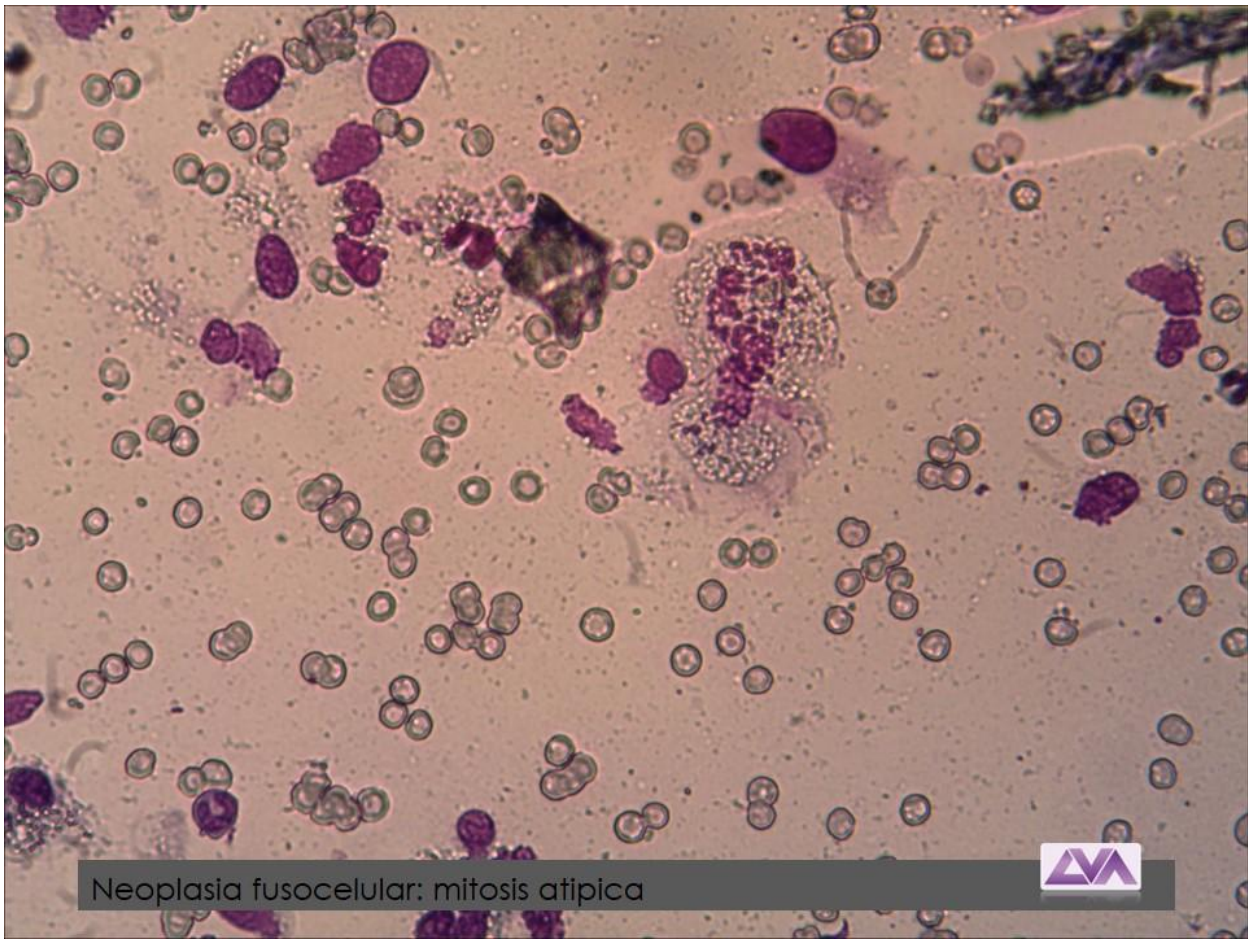


Células fusiformes con atipias: hemangiopericitoma

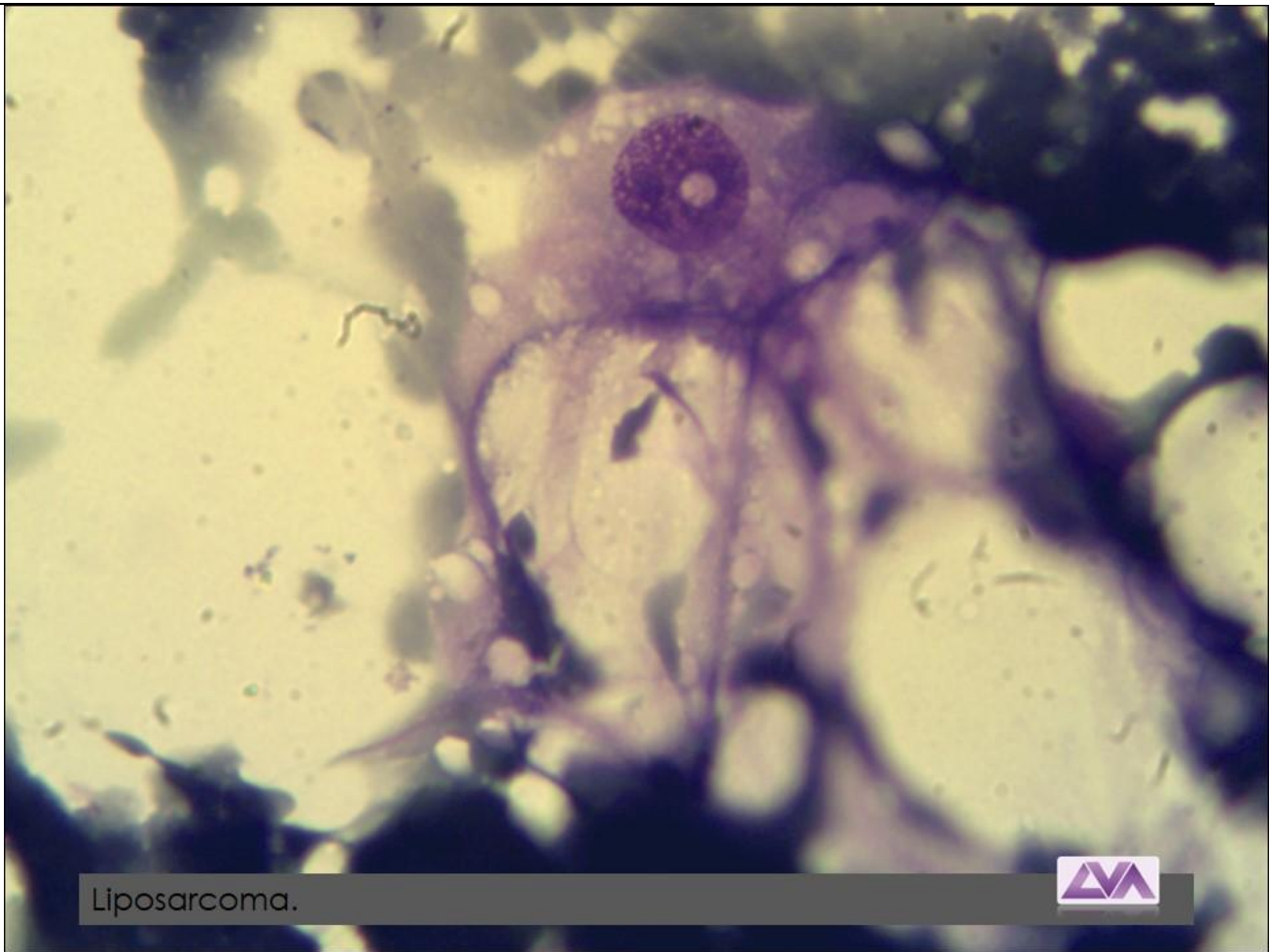


Células fusiformes con atipias



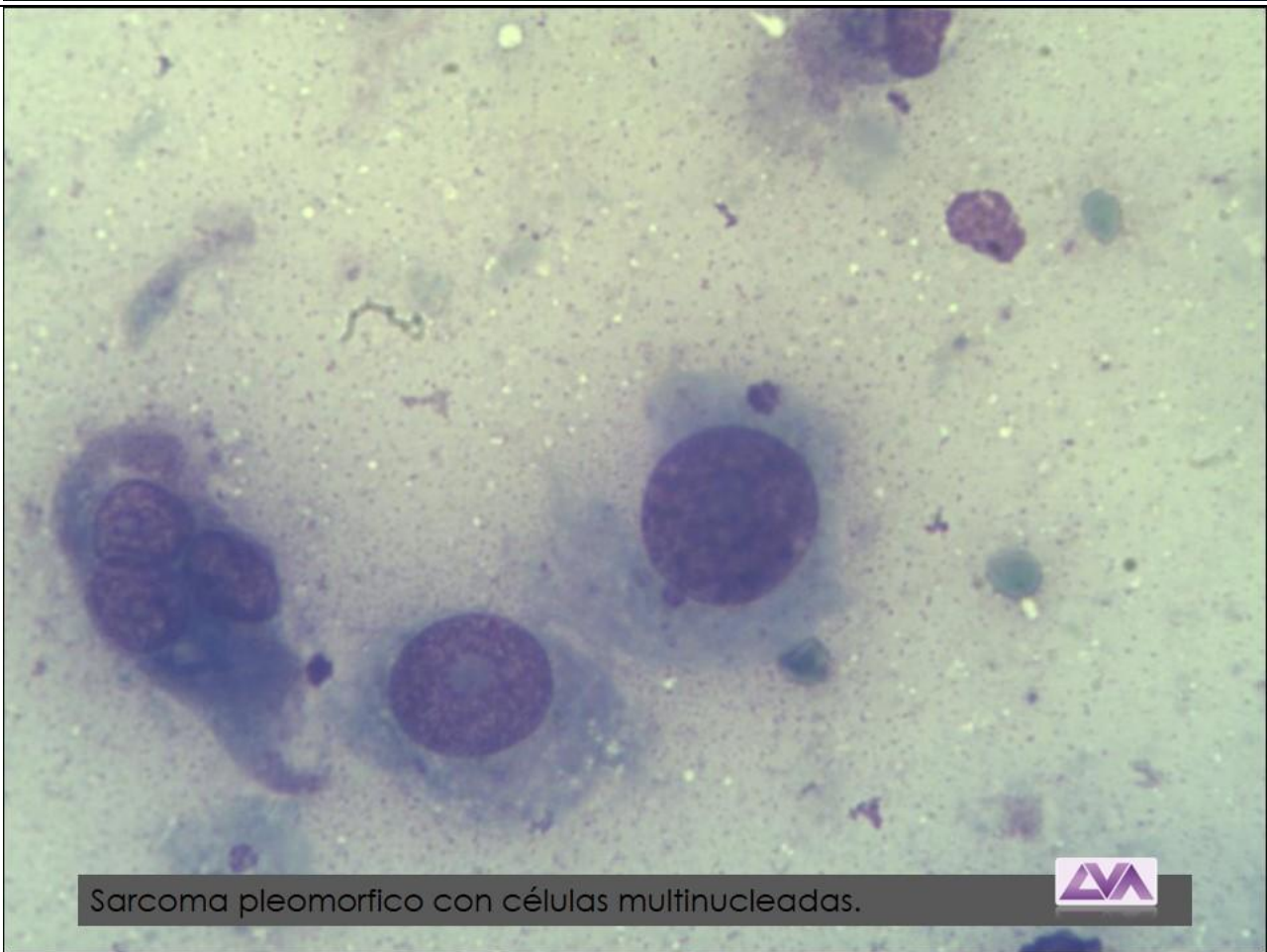
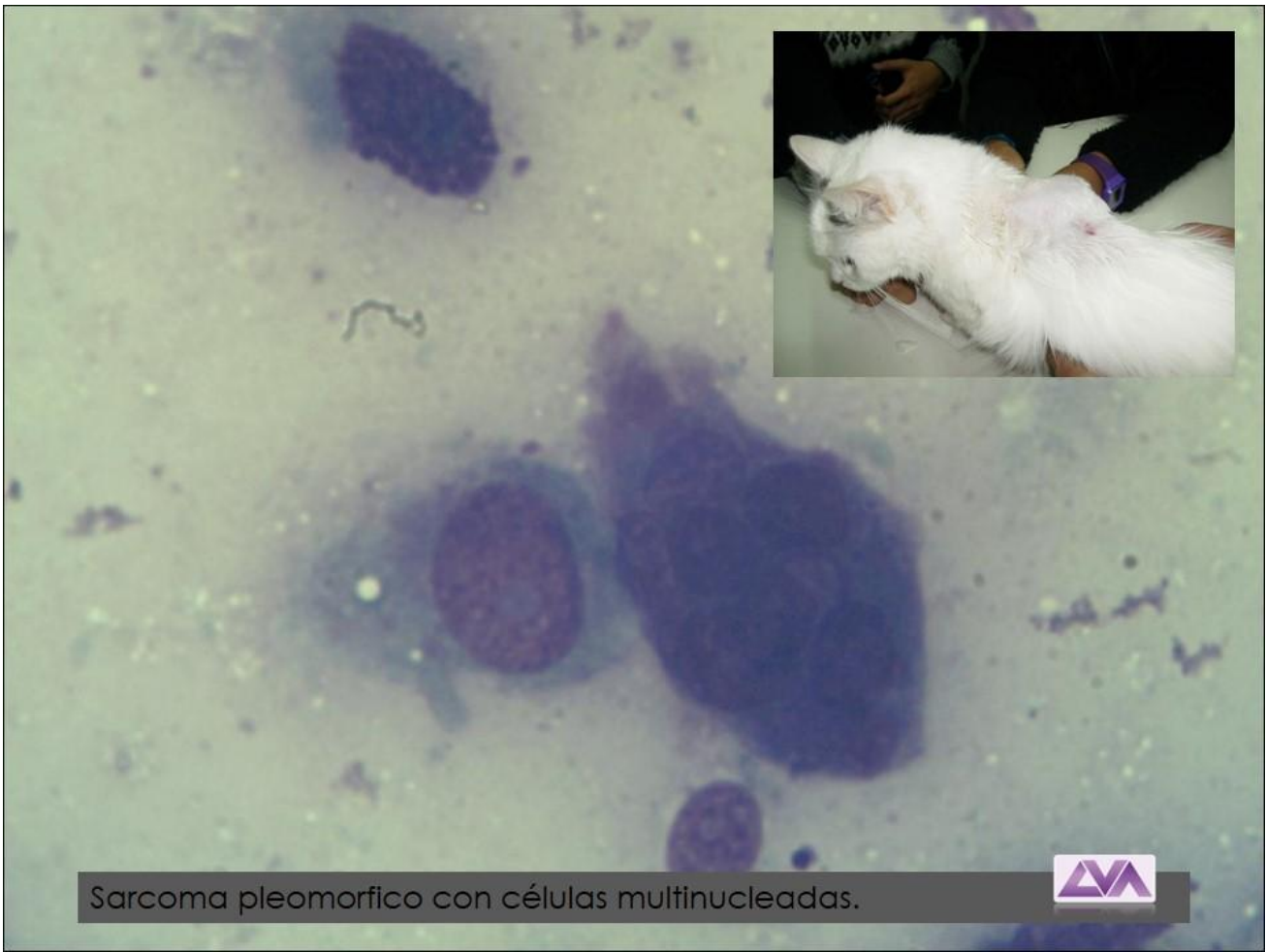


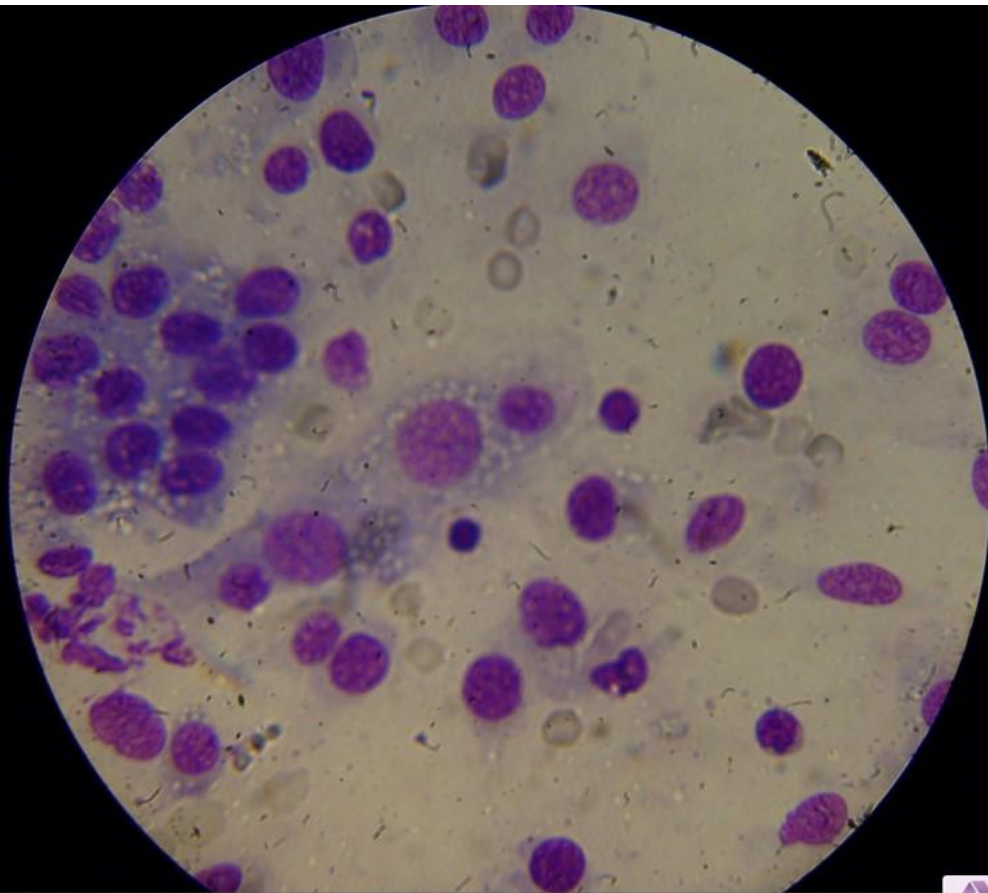
Neoplasia fusocelular: mitosis atípica



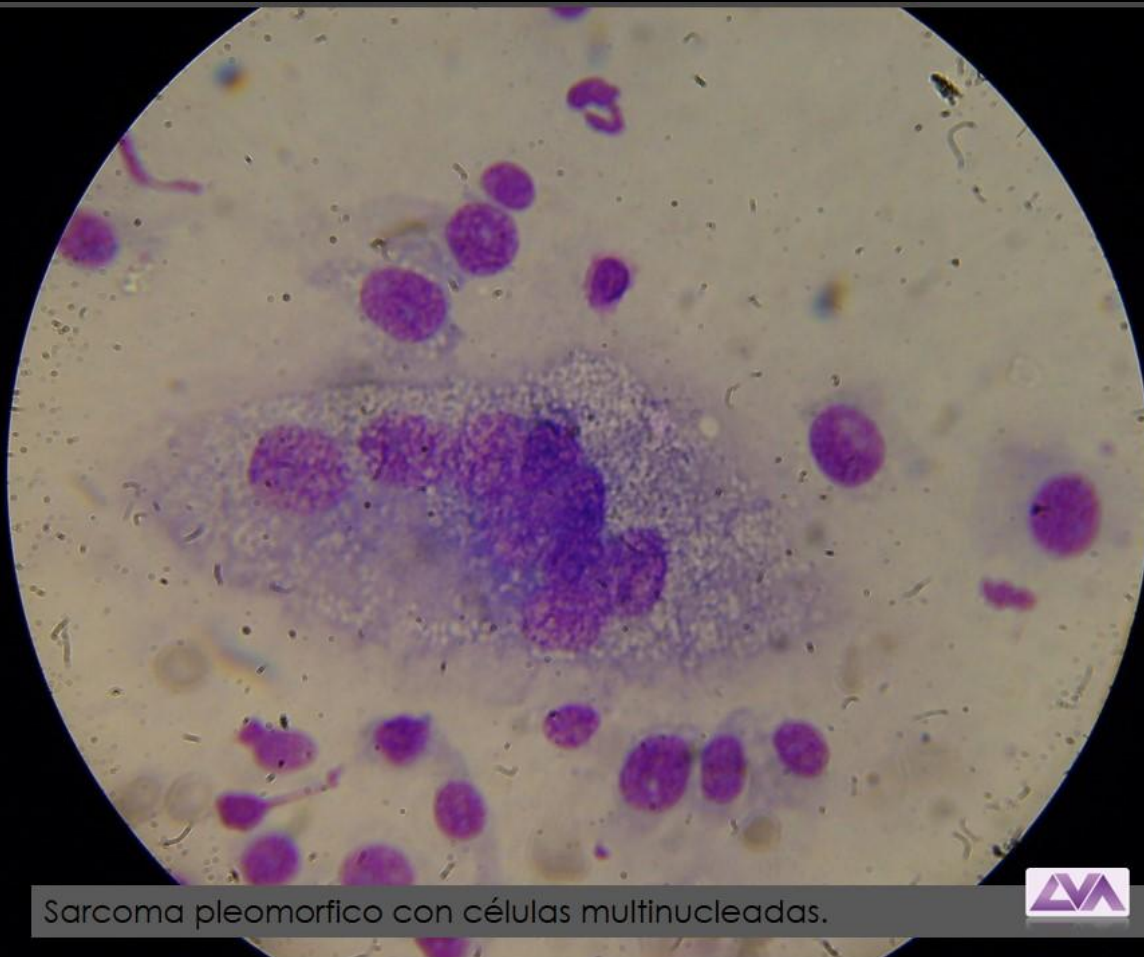
Liposarcoma.





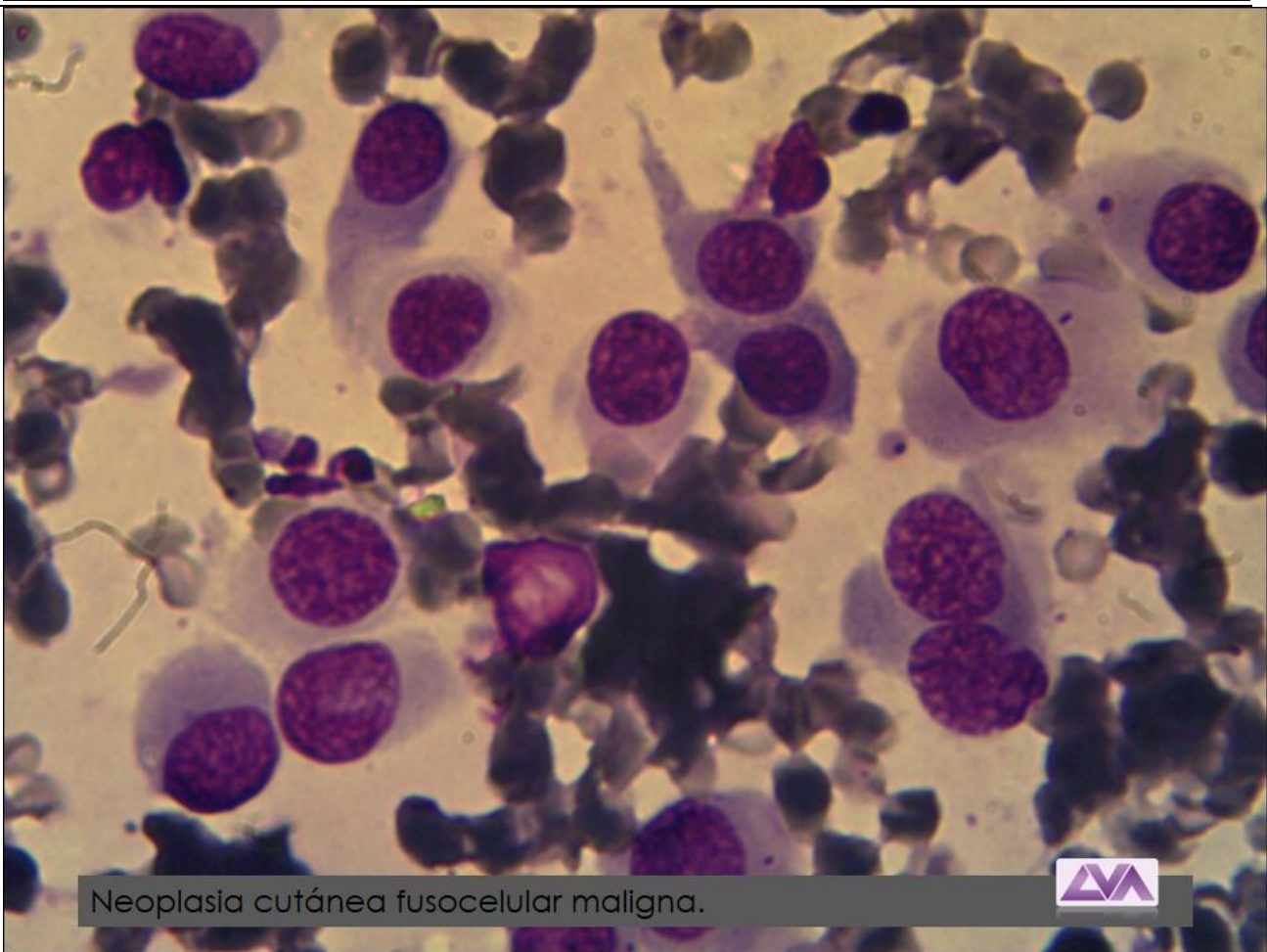
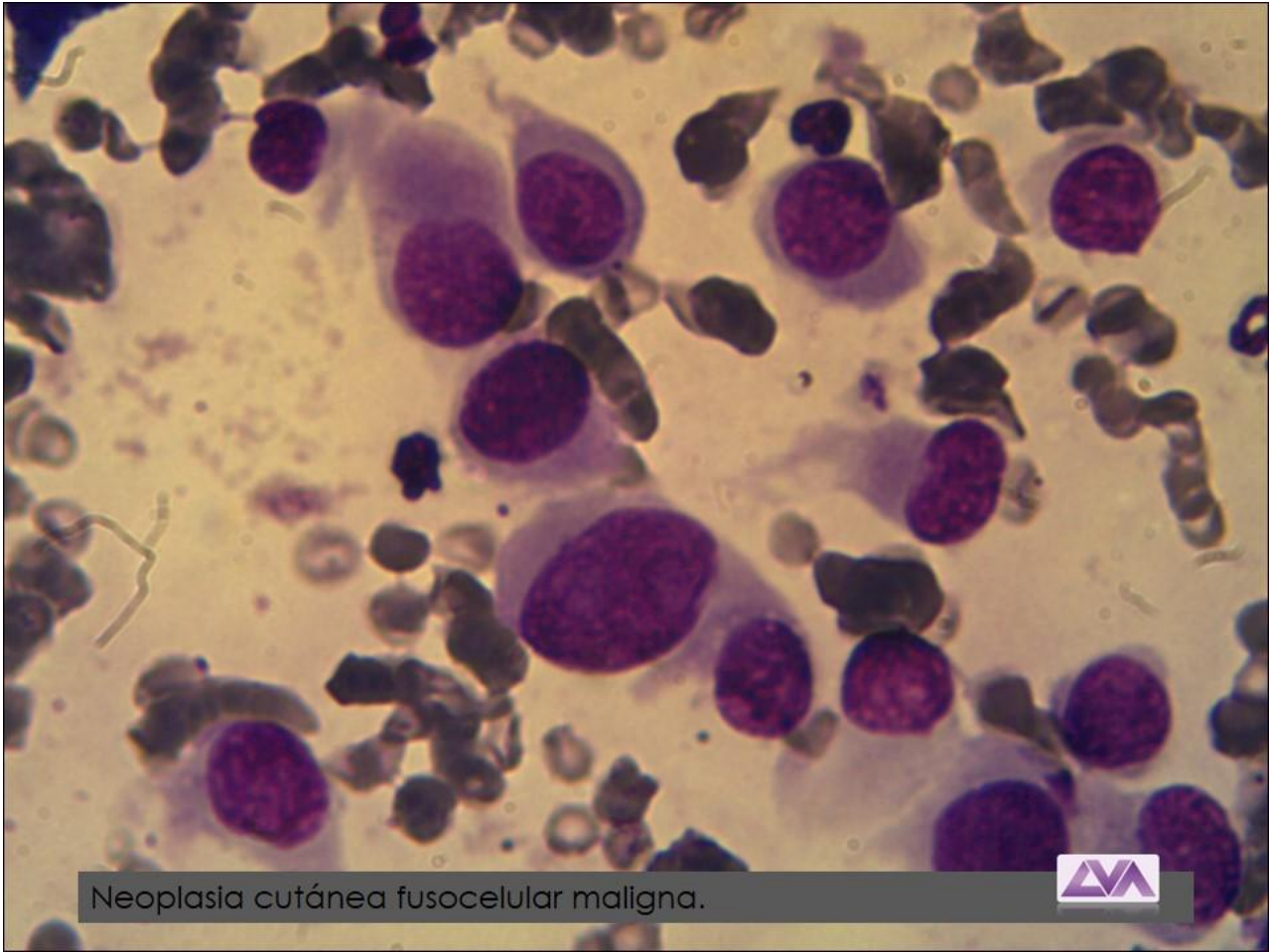


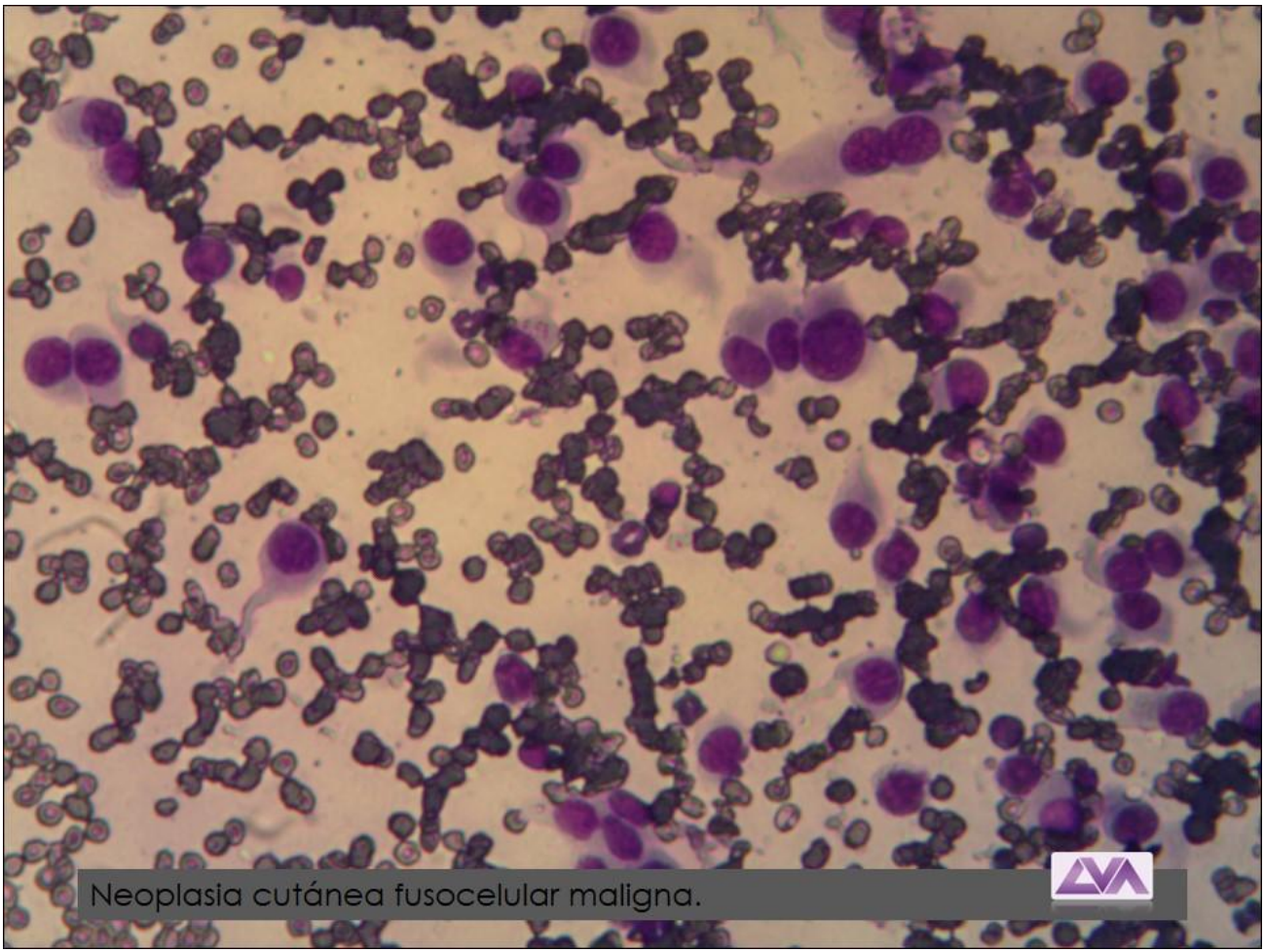
Sarcoma pleomorfico con células multinucleadas.



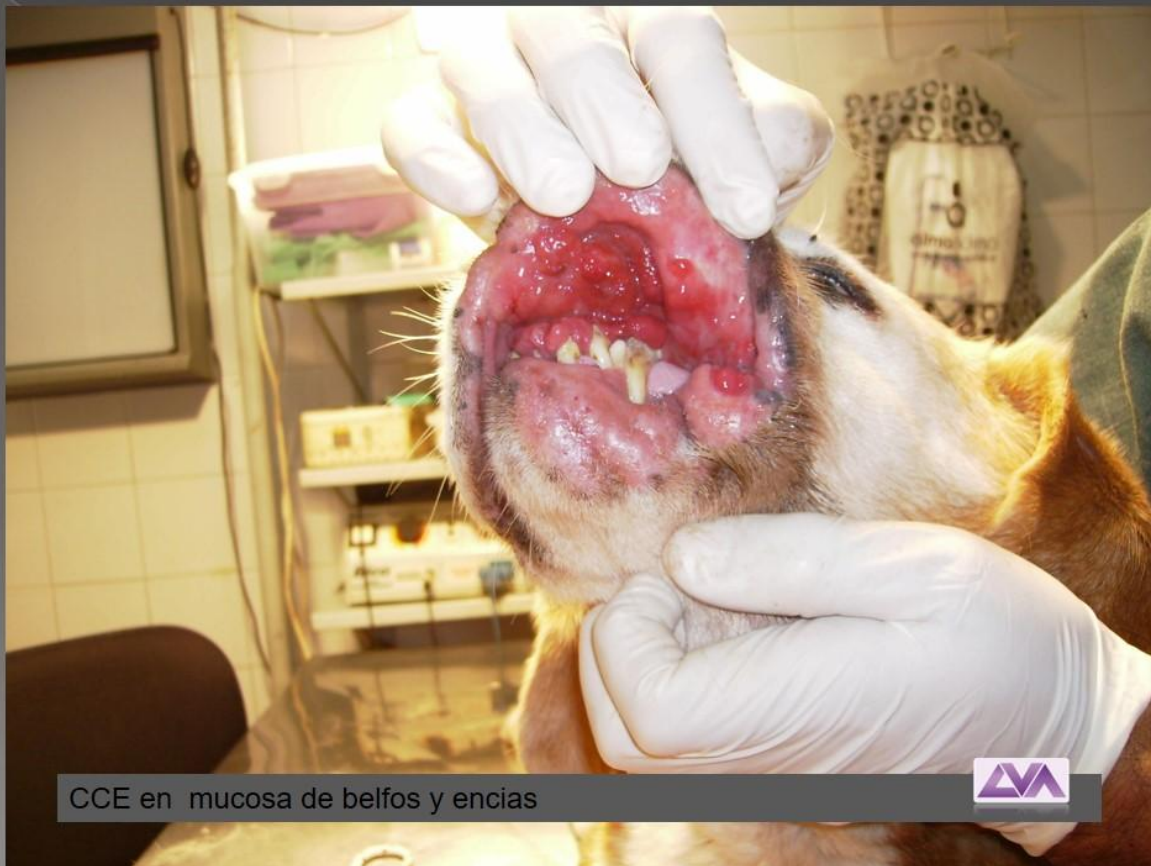Sarcoma pleomorfico con células multinucleadas.



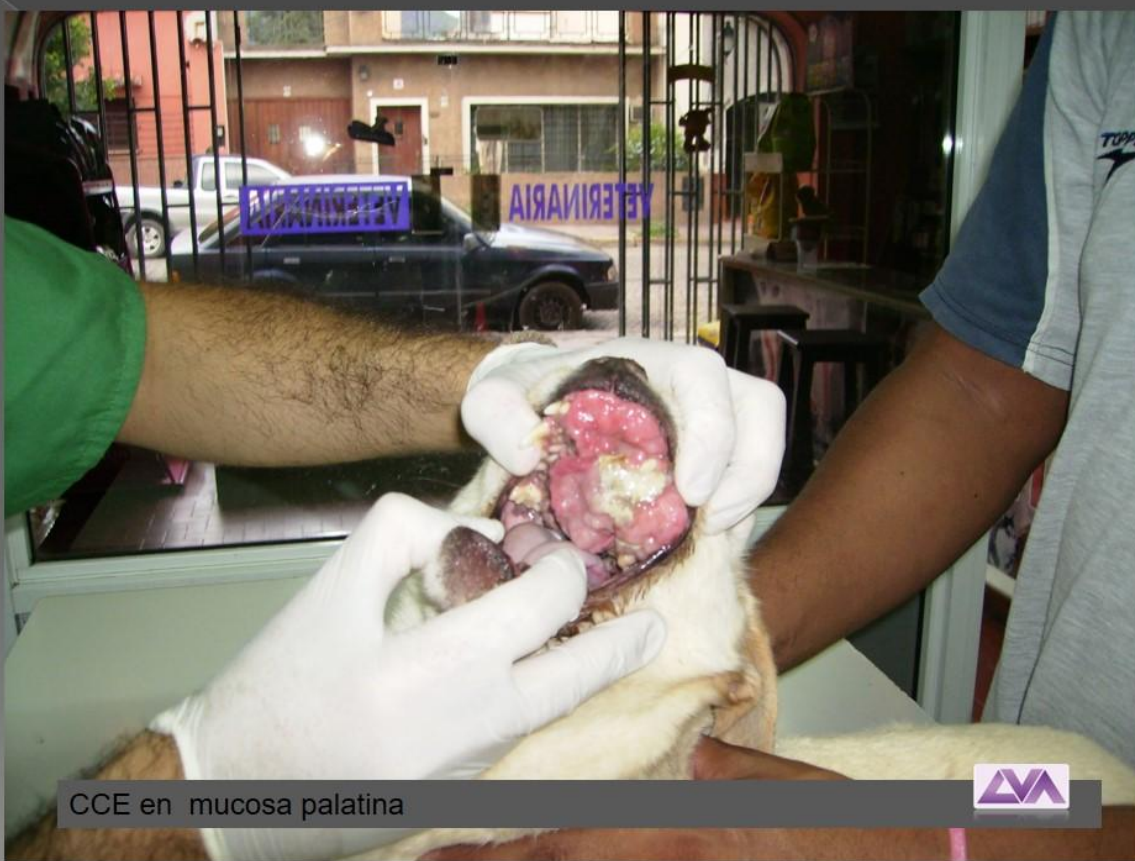



ATLAS: IMÁGENES CITOLOGIA DE CAVIDAD ORAL

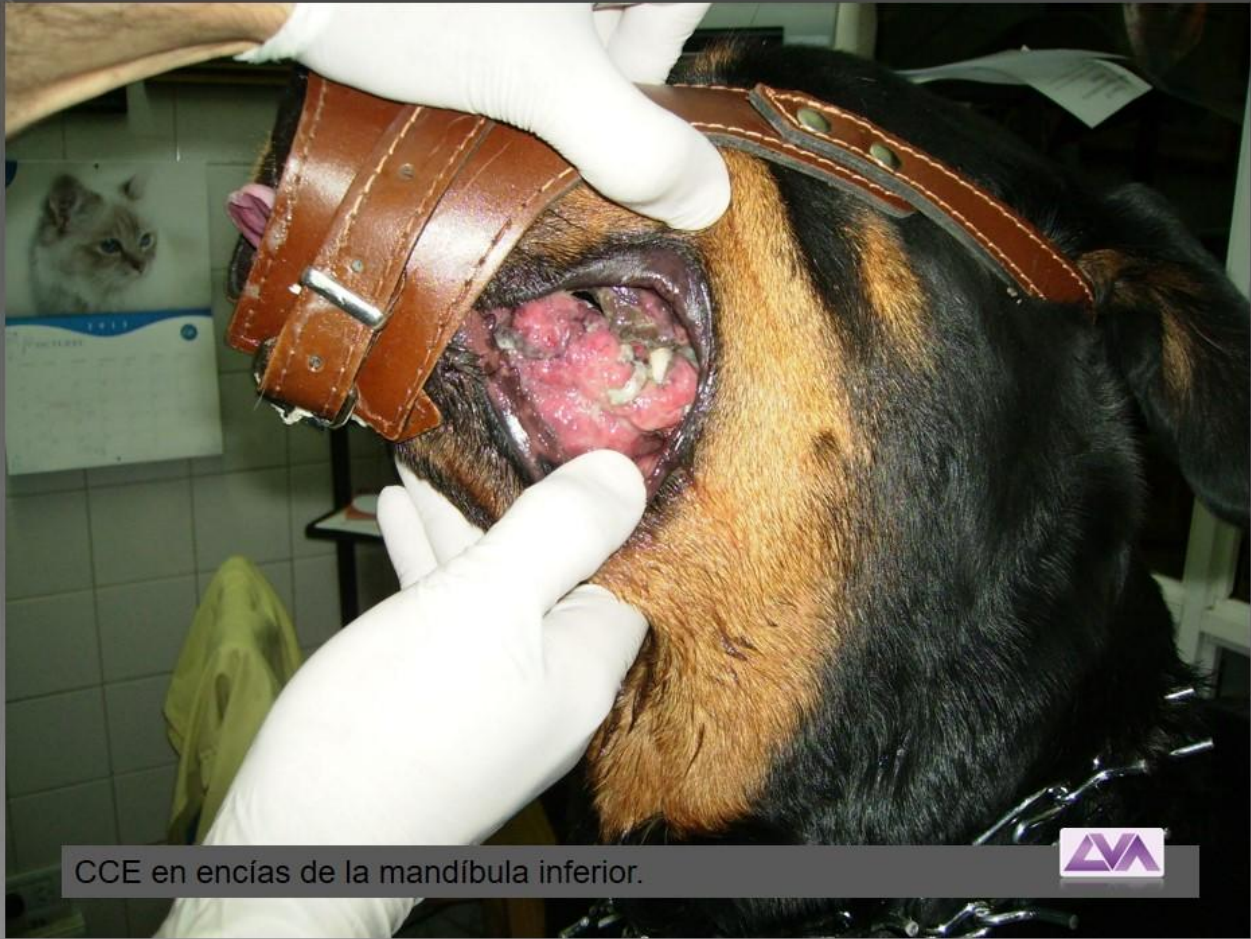

CCE en mucosa de bellos y encias

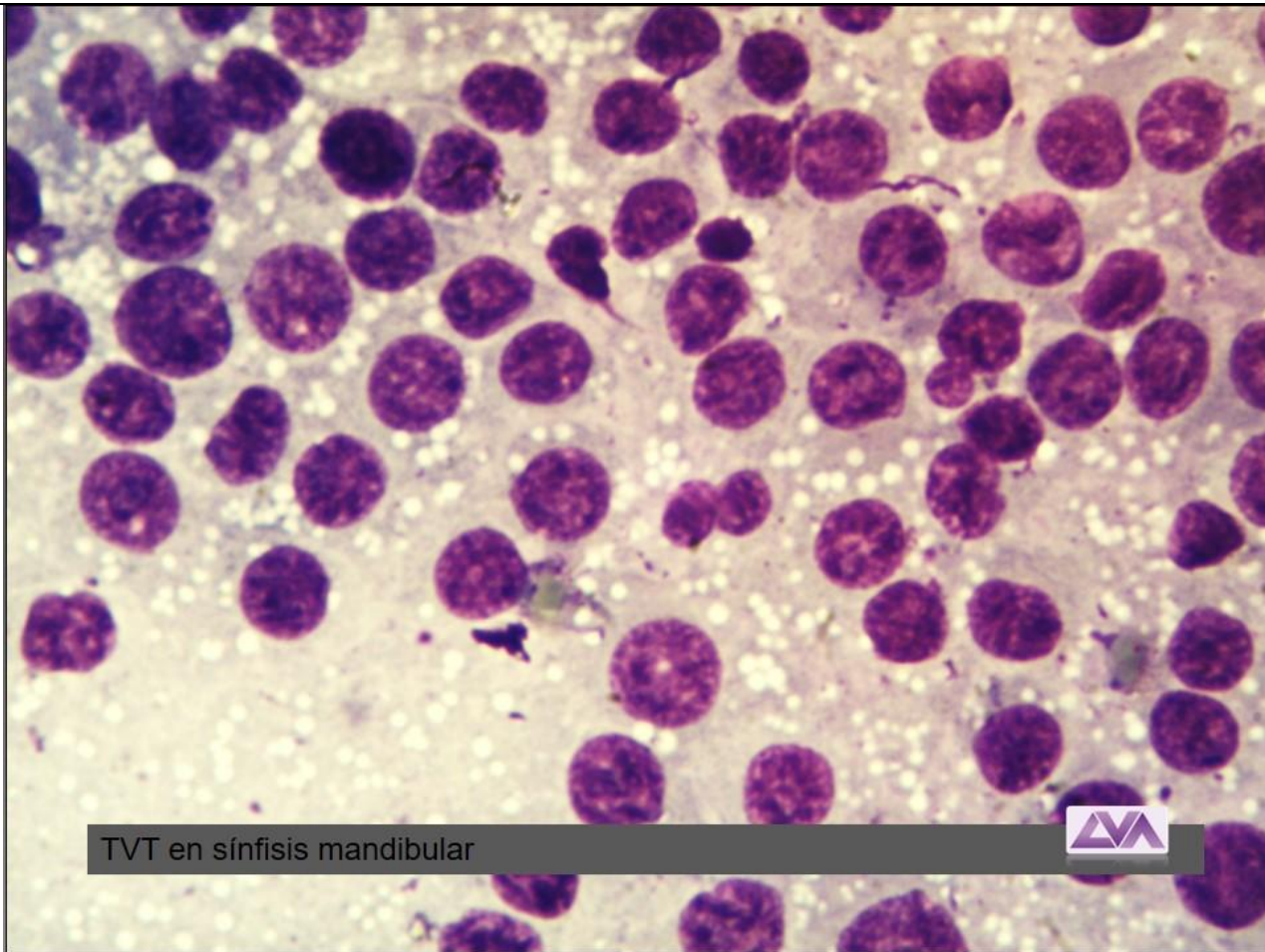


CCE en mucosa palatina



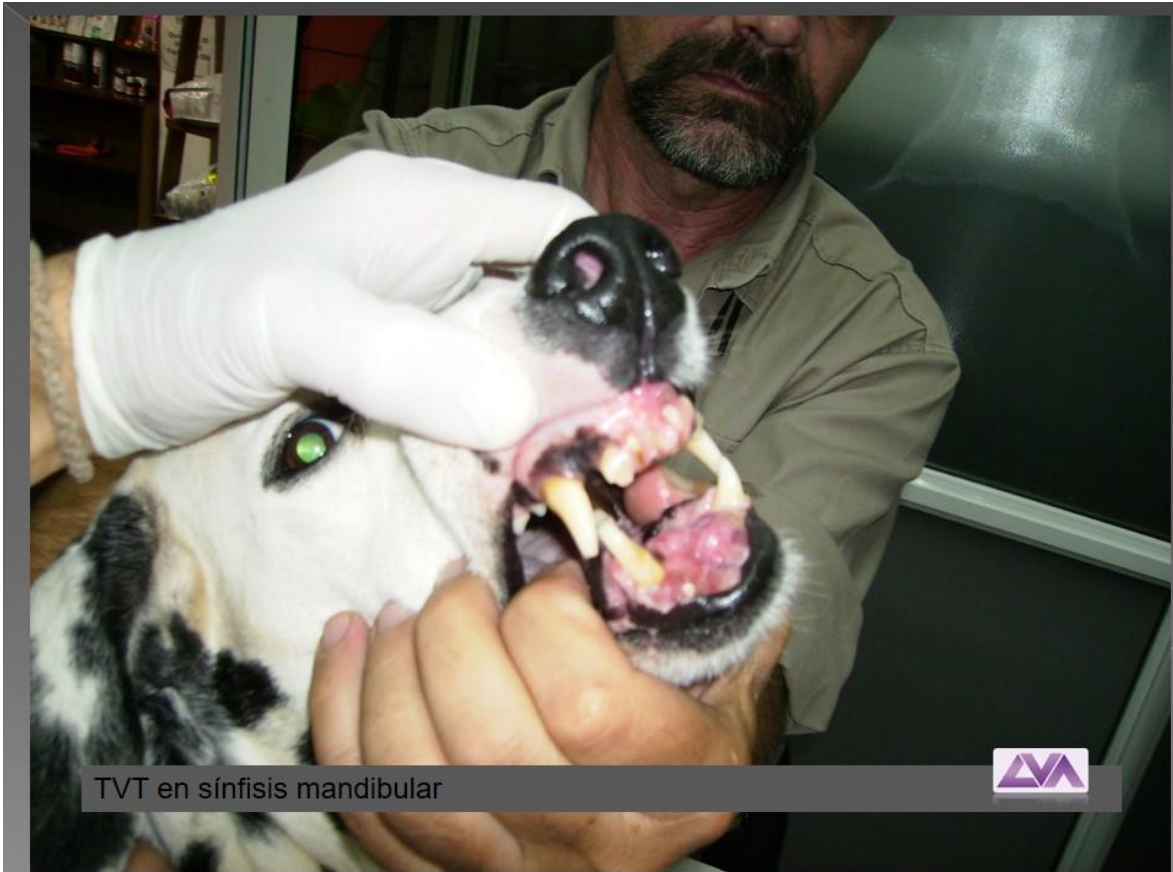

CCE en encías de la mandíbula inferior.

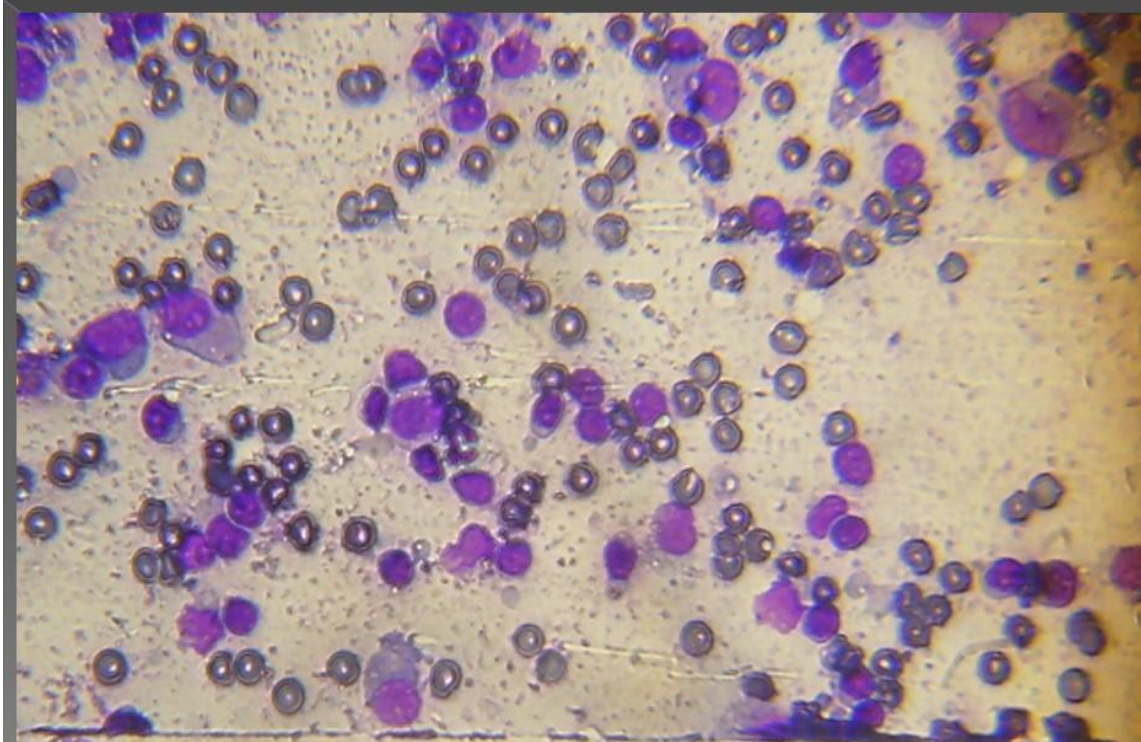


TVT en sínfisis mandibular



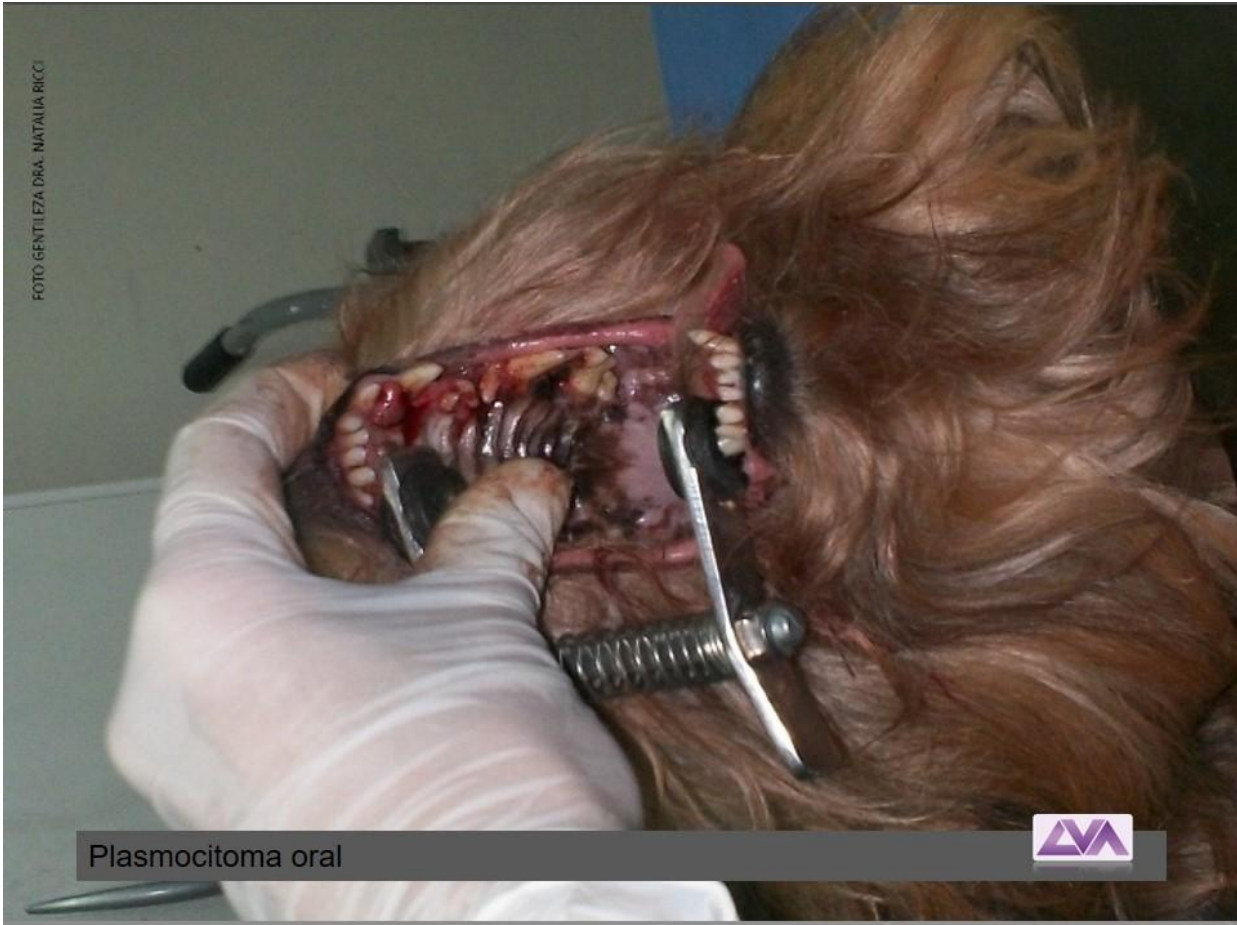

TVT en sínfisis mandibular

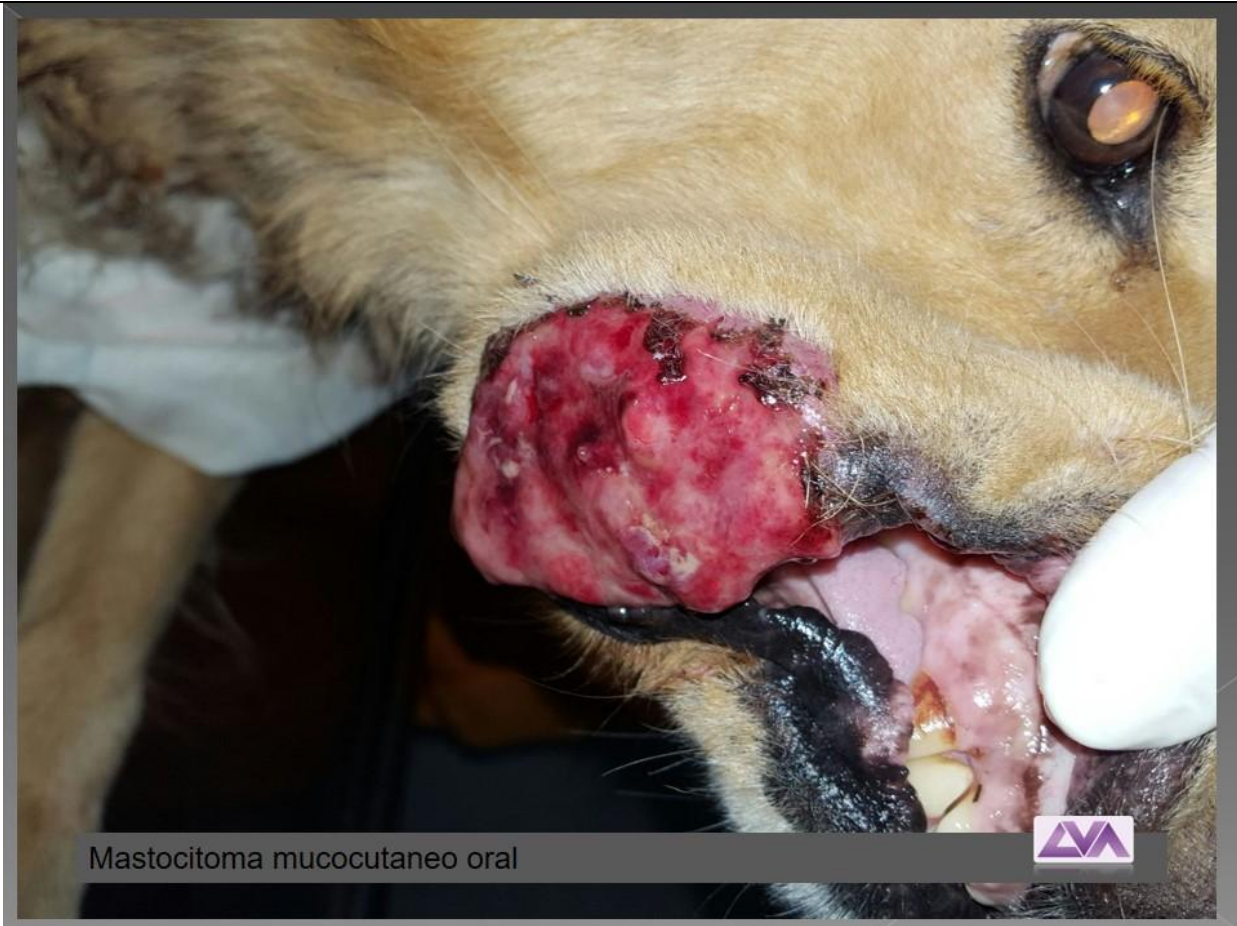

Plasmocitoma oral



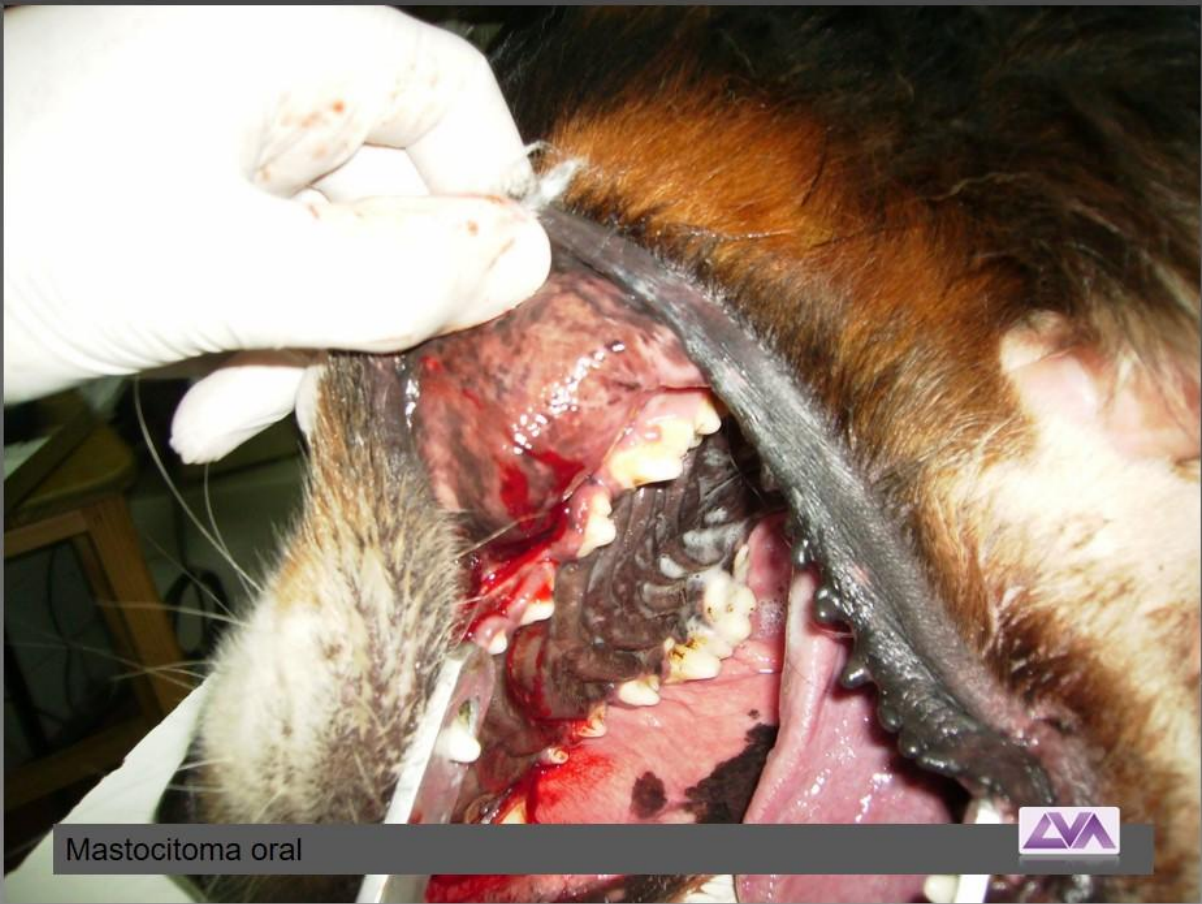


Plasmocitoma oral

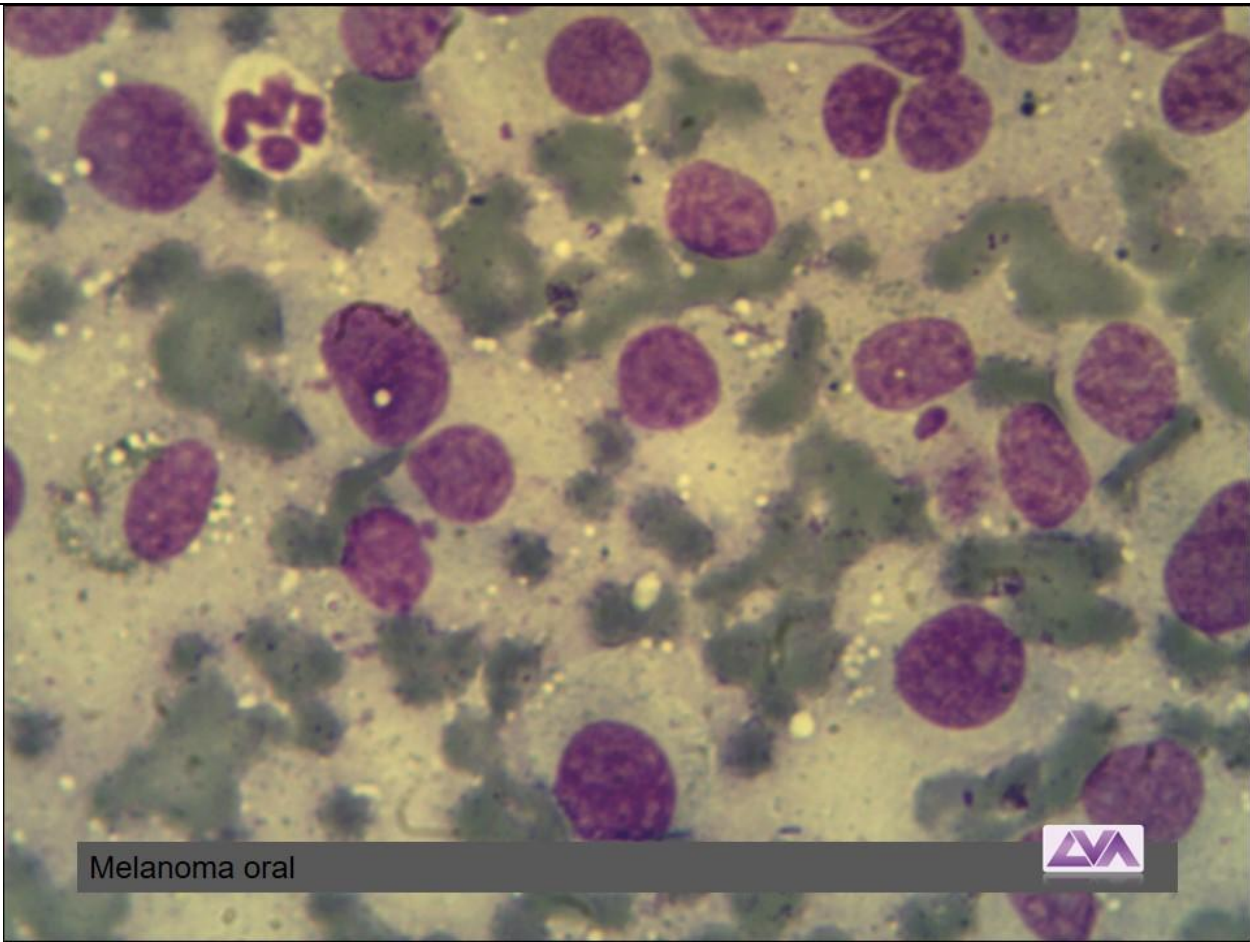


Mastocitoma mucocutaneo oral



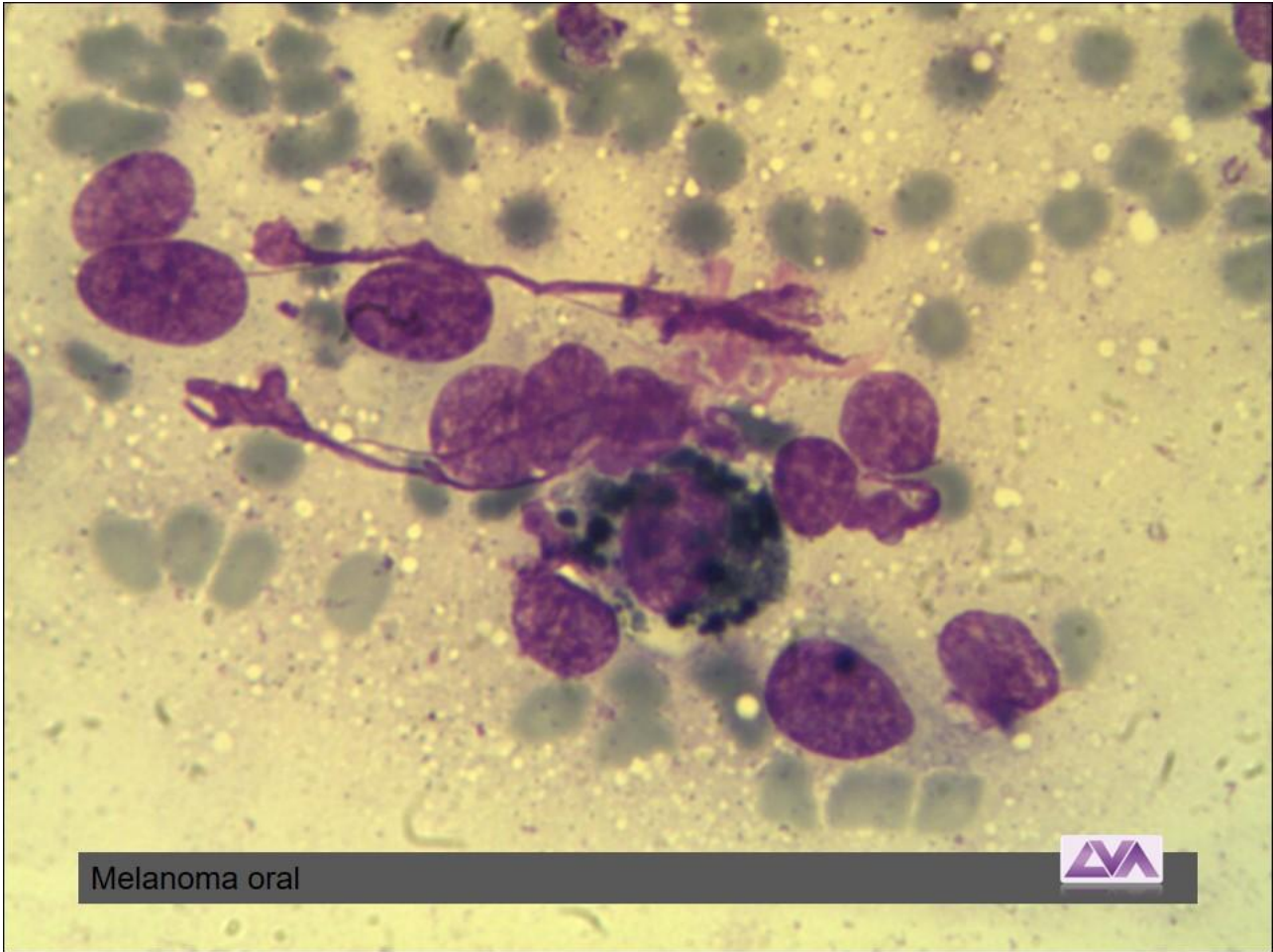


Mastocitoma oral

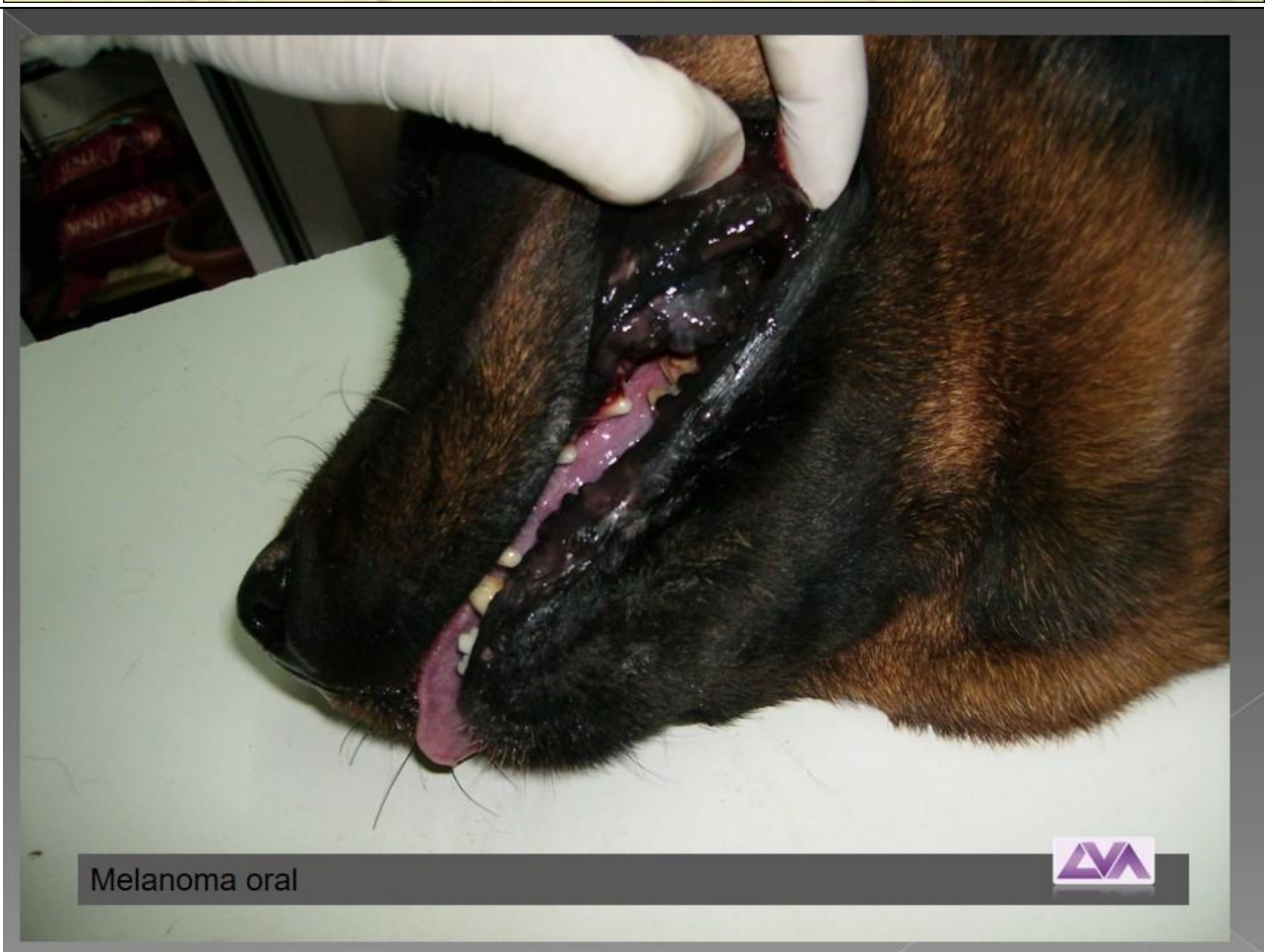


Melanoma oral



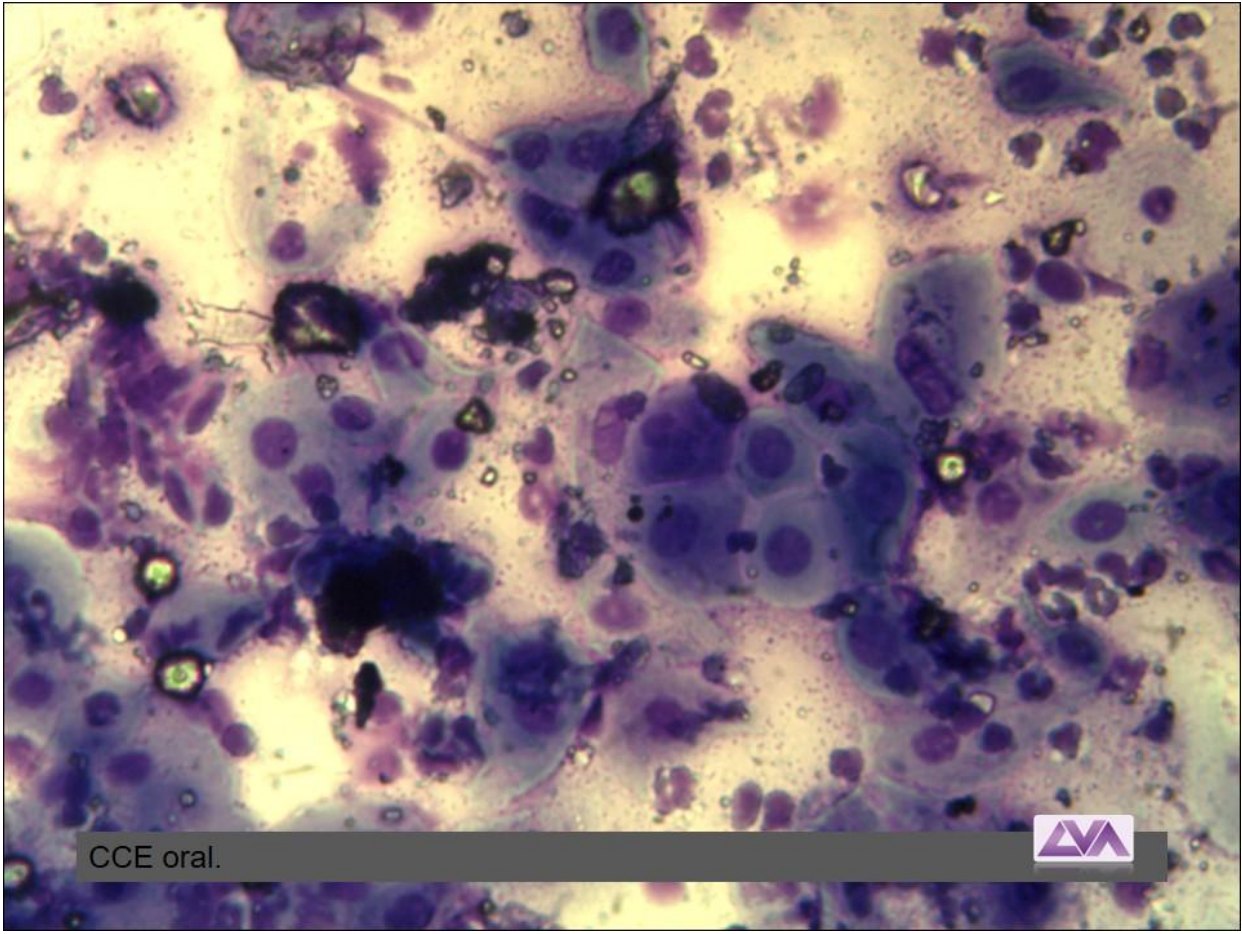


Melanoma oral



Melanoma oral

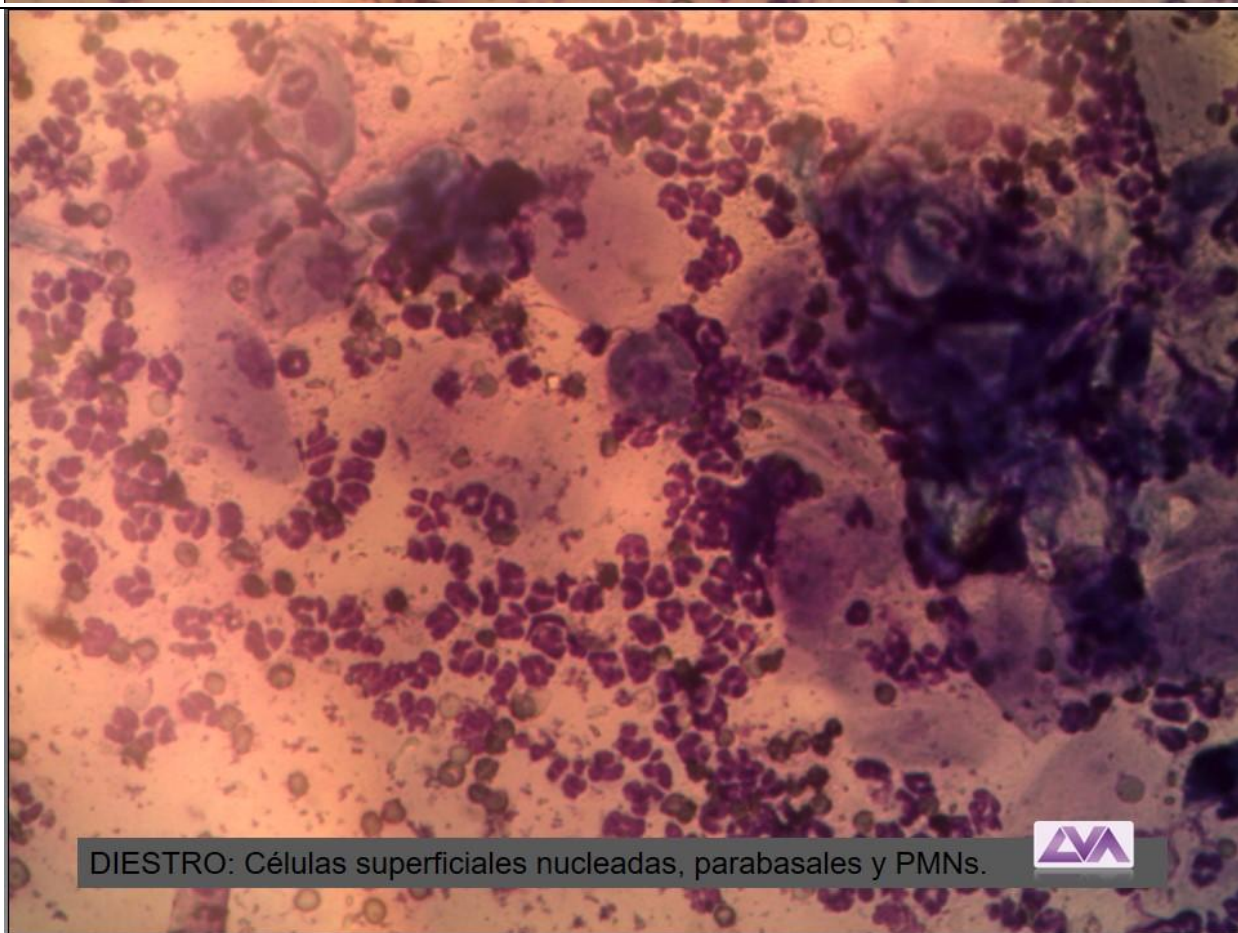
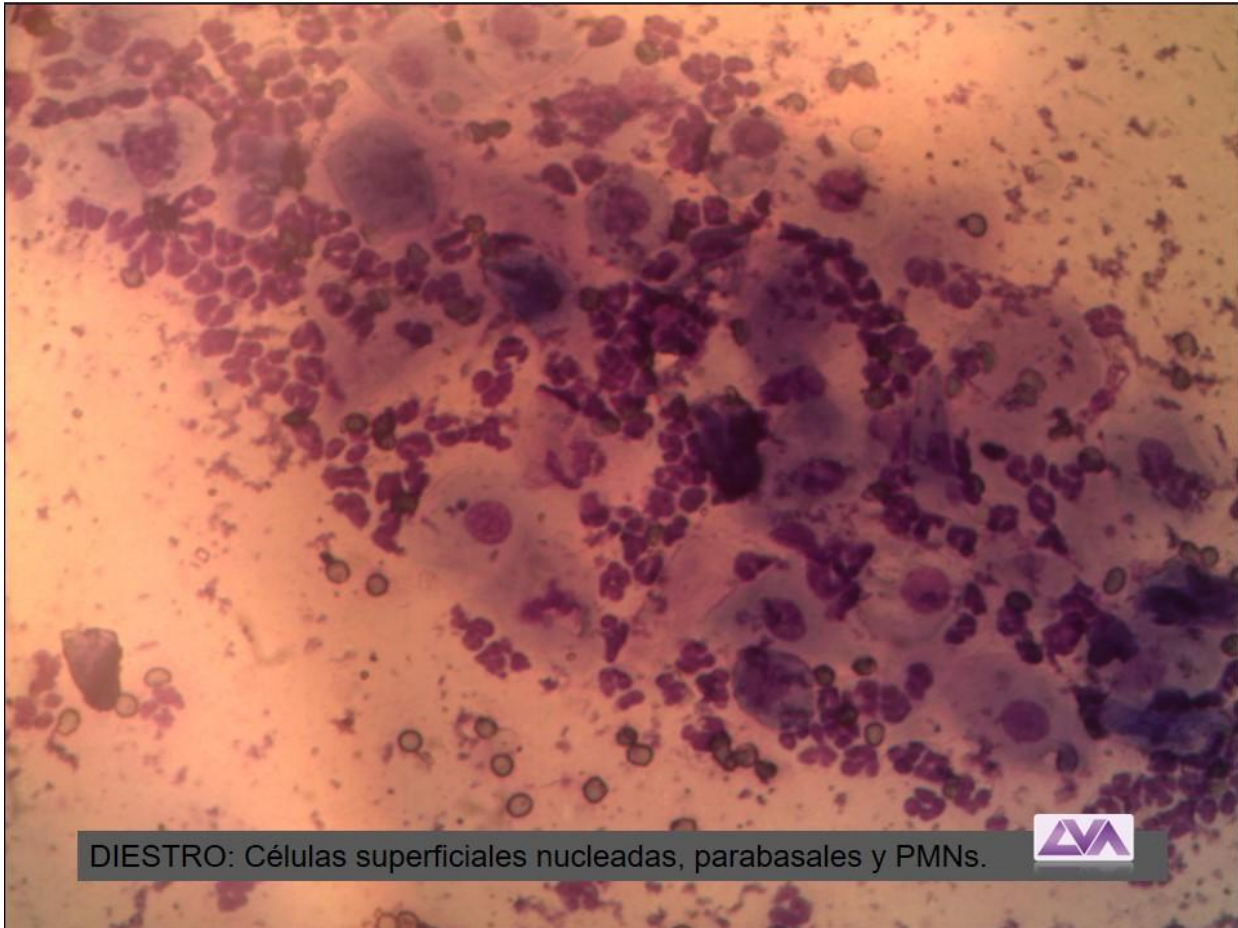


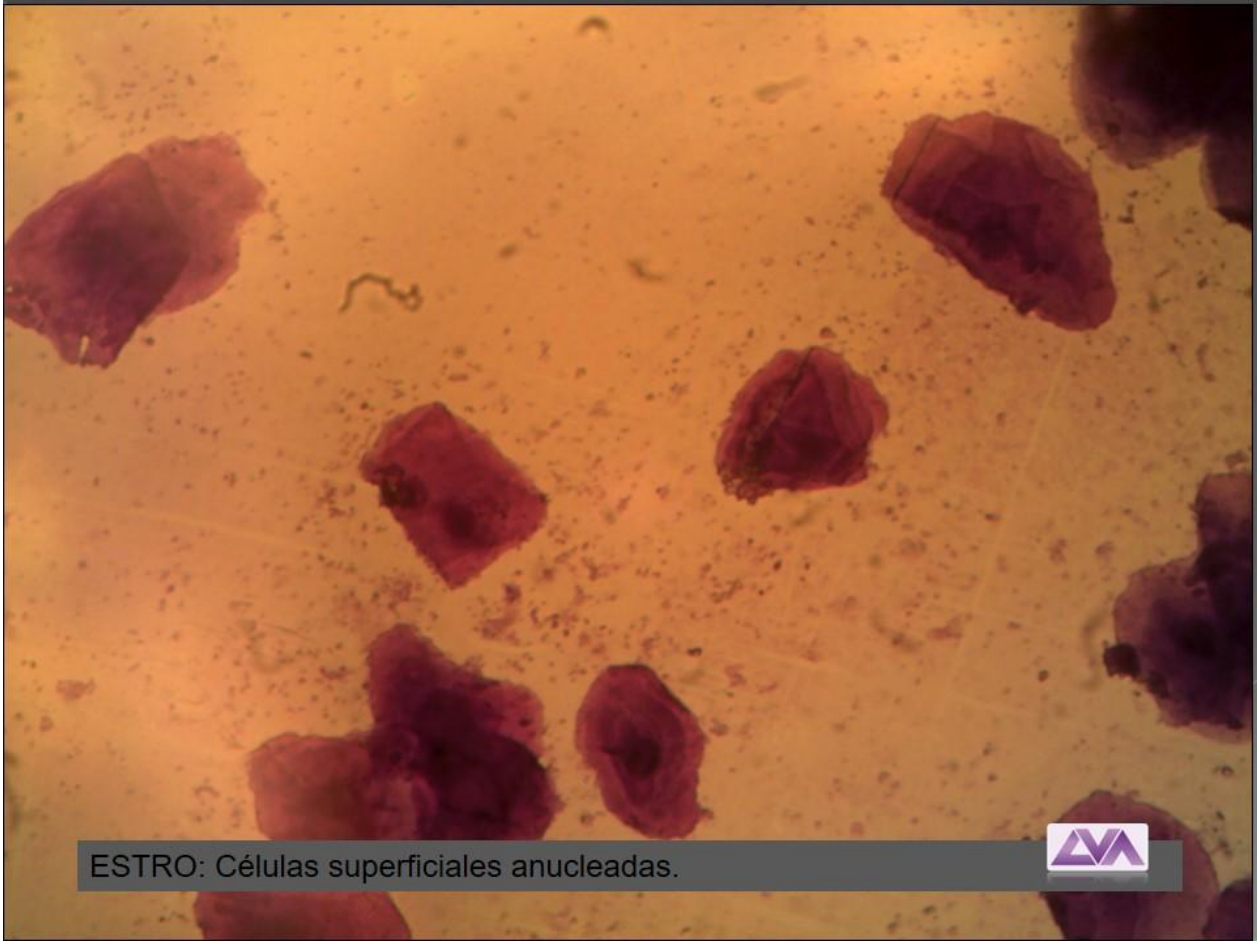

CCE oral.

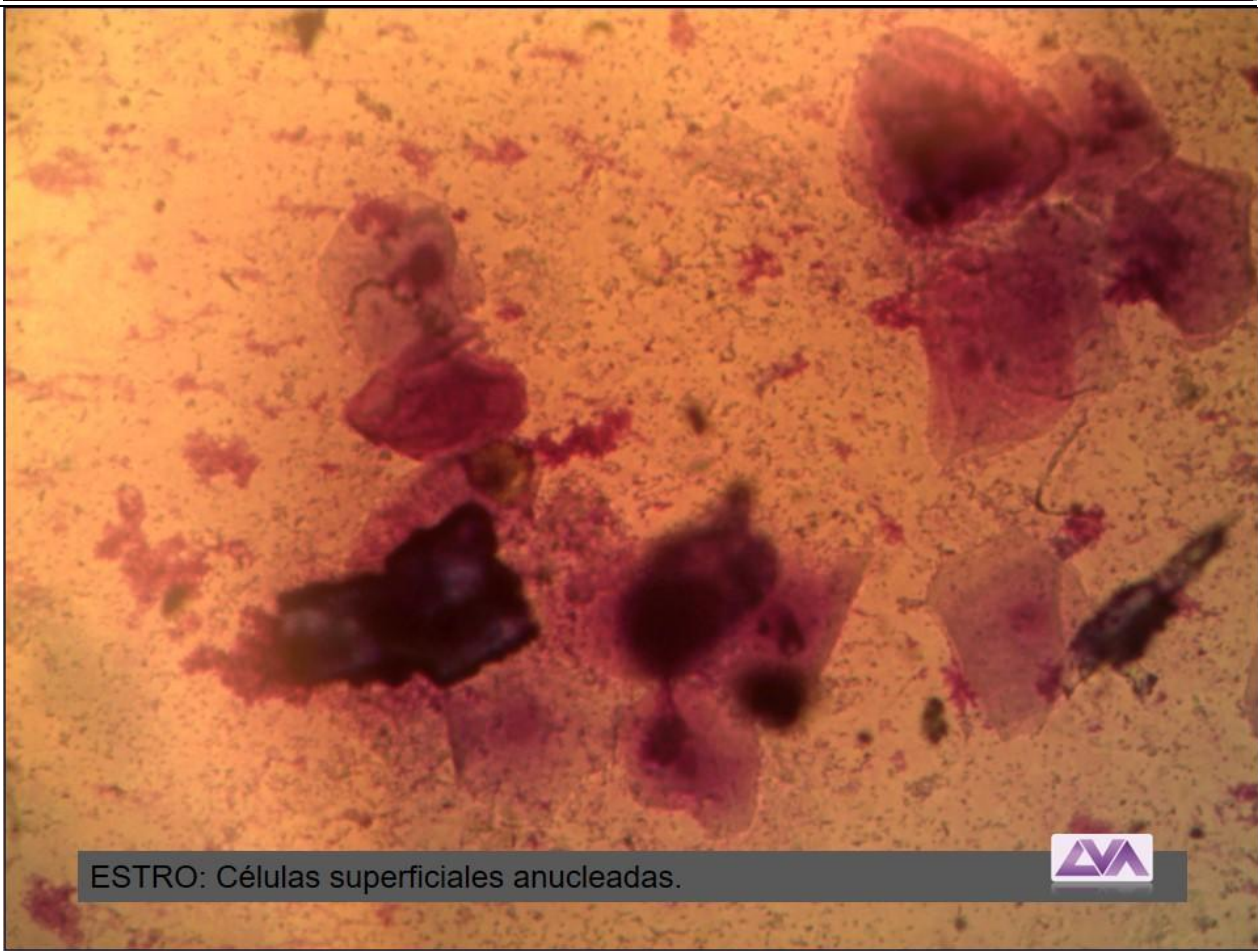


ATLAS DE CITOLOGIA VAGINAL



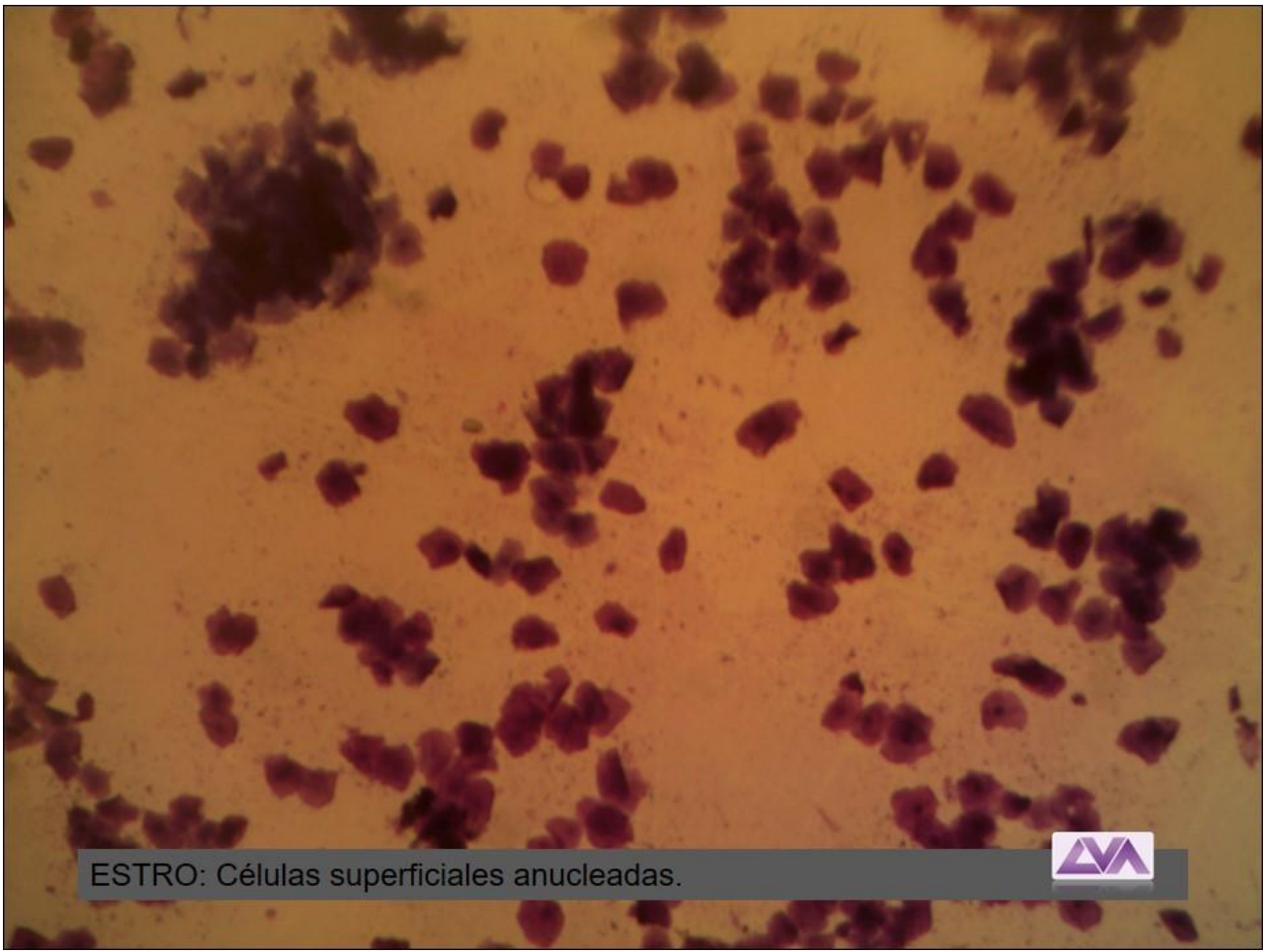


ESTRO: Células superficiales anucleadas.

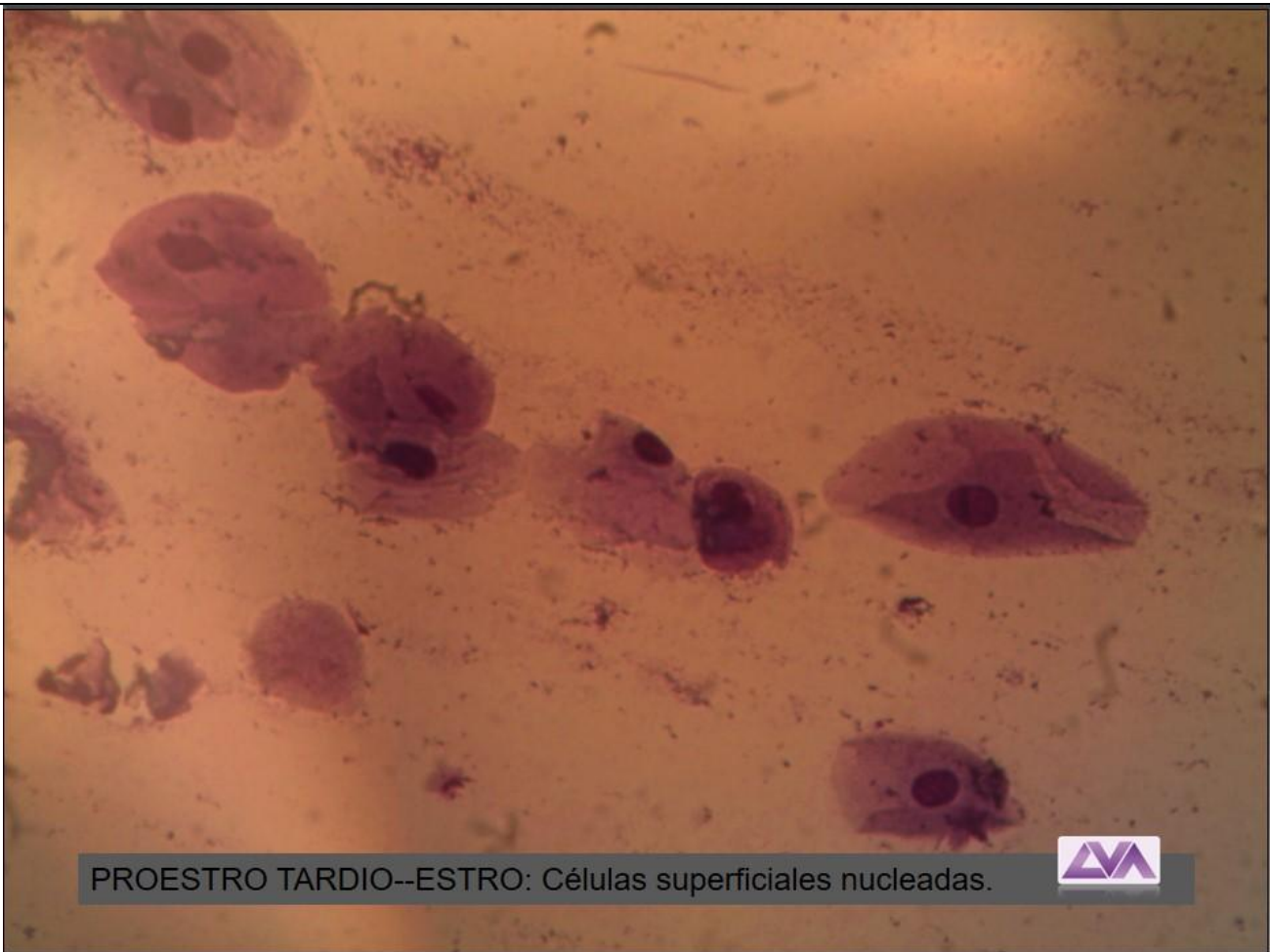


ESTRO: Células superficiales anucleadas.



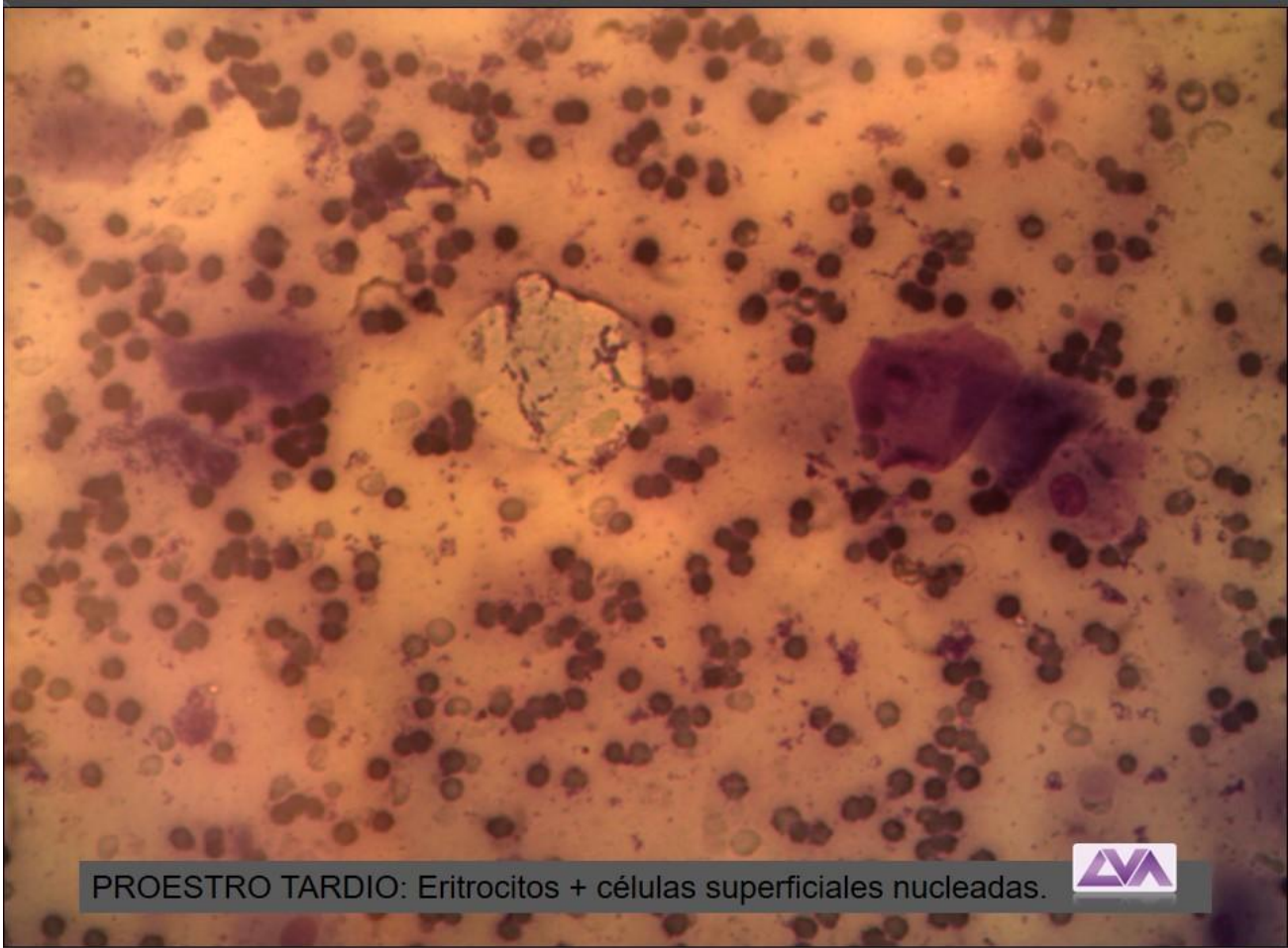

ESTRO: Células superficiales anucleadas.

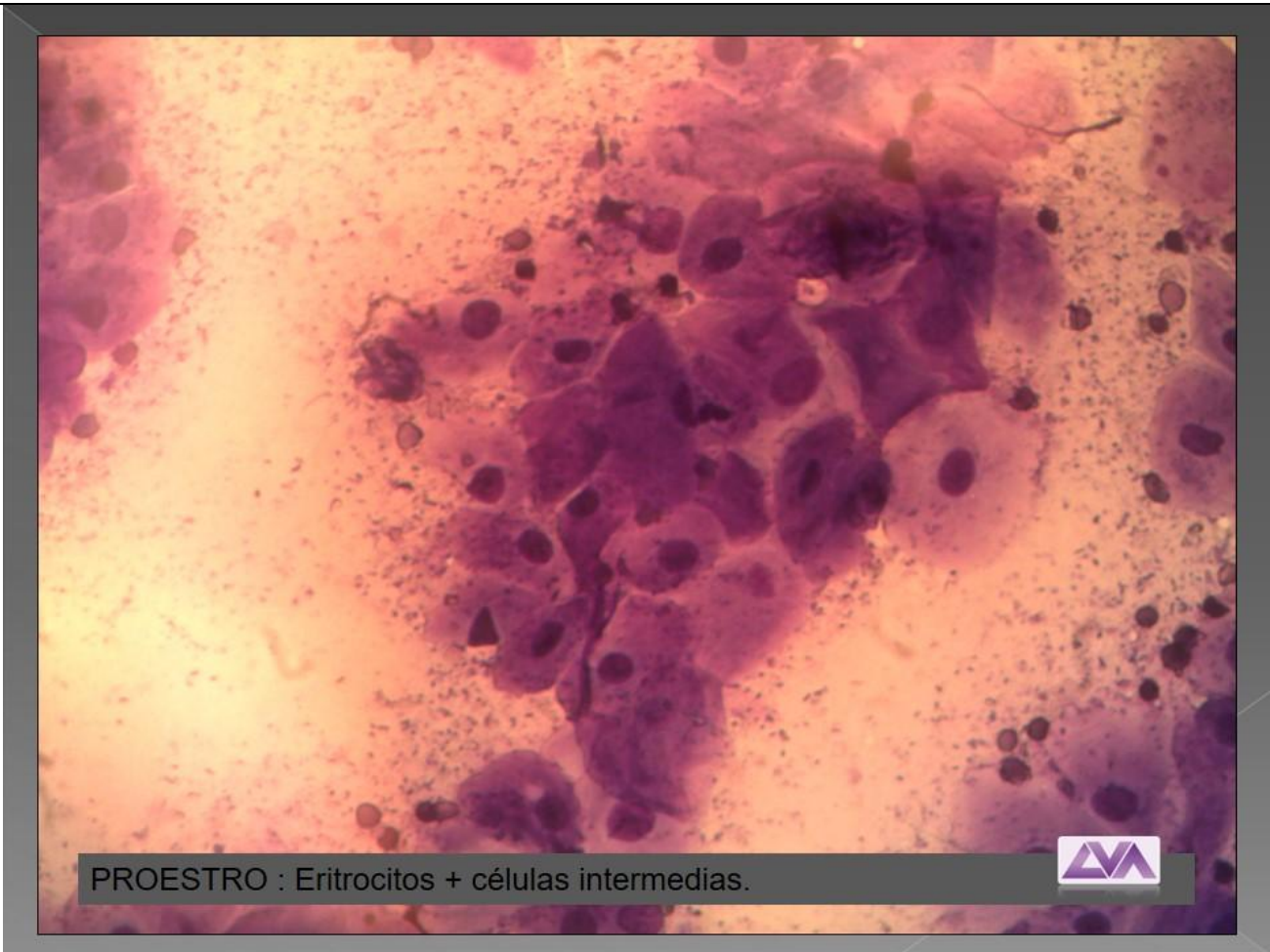

PROESTRO TARDIO--ESTRO: Células superficiales nucleadas.





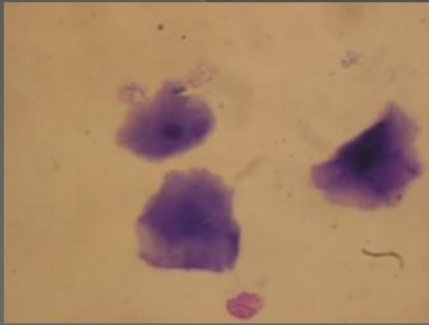
PROESTRO TARDIO: Eritrocitos + células superficiales nucleadas.



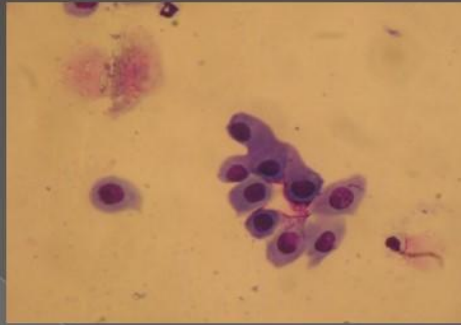
PROESTRO : Eritrocitos + células intermedias.



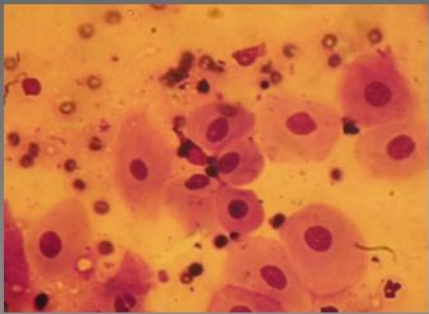
Citología Vaginal Exfoliativa



Células superficiales y escamas

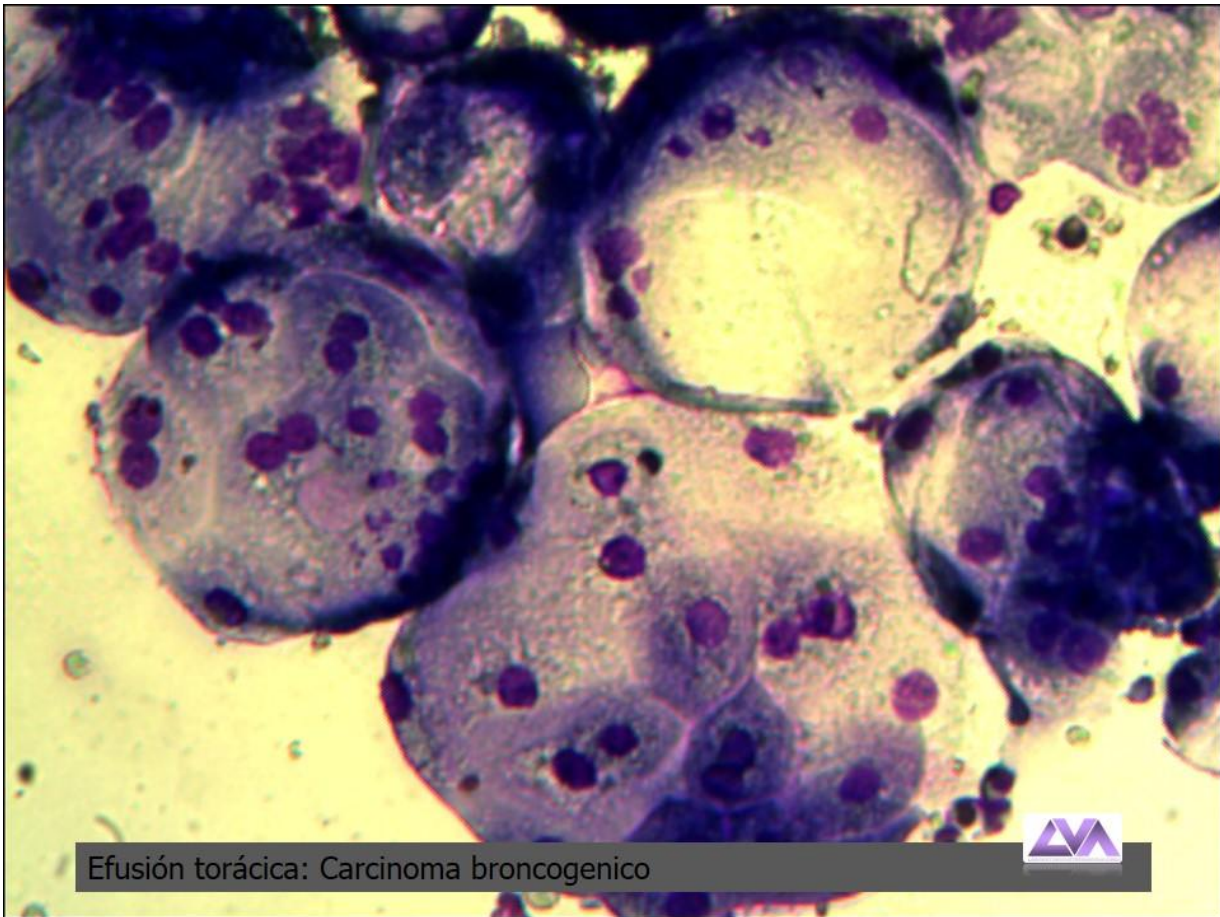


Células parabasales

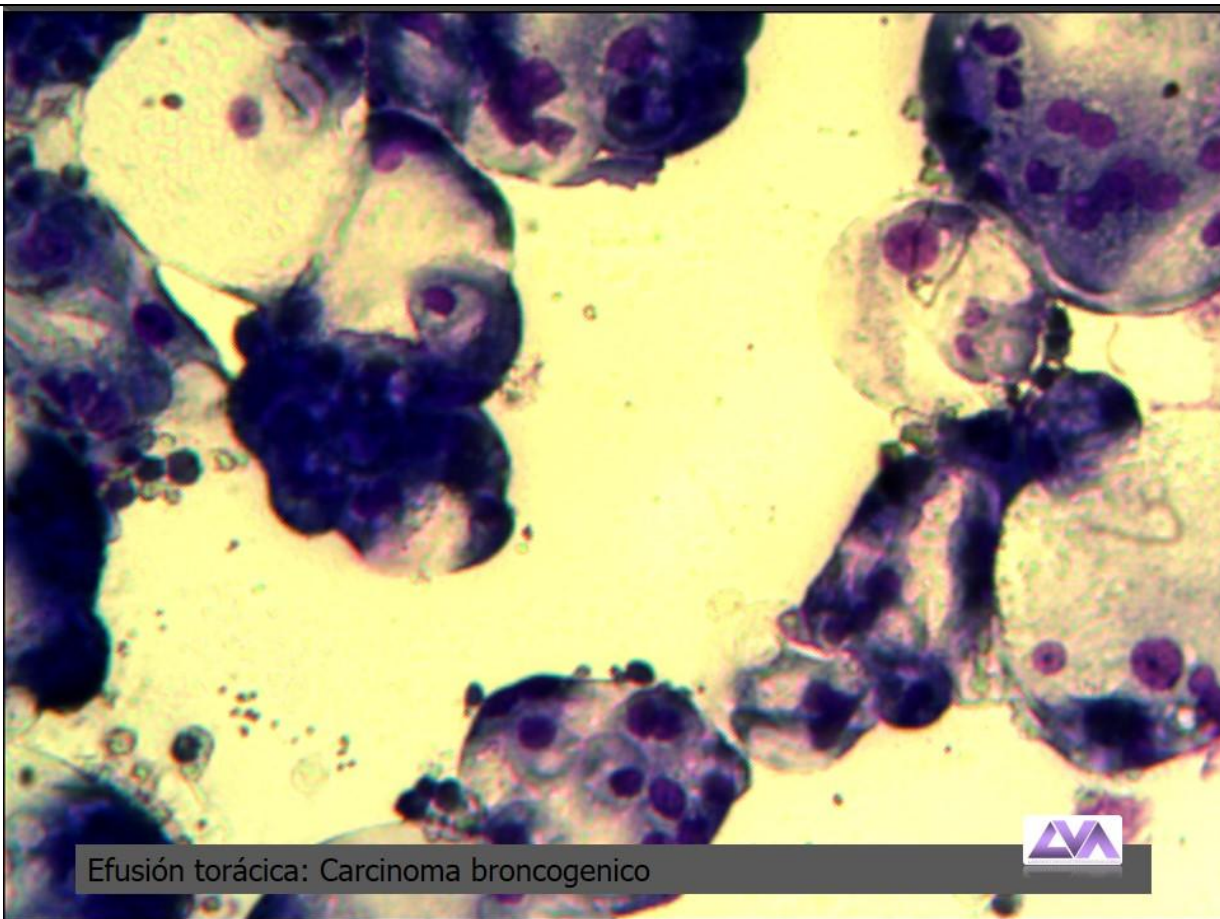


Células intermedias

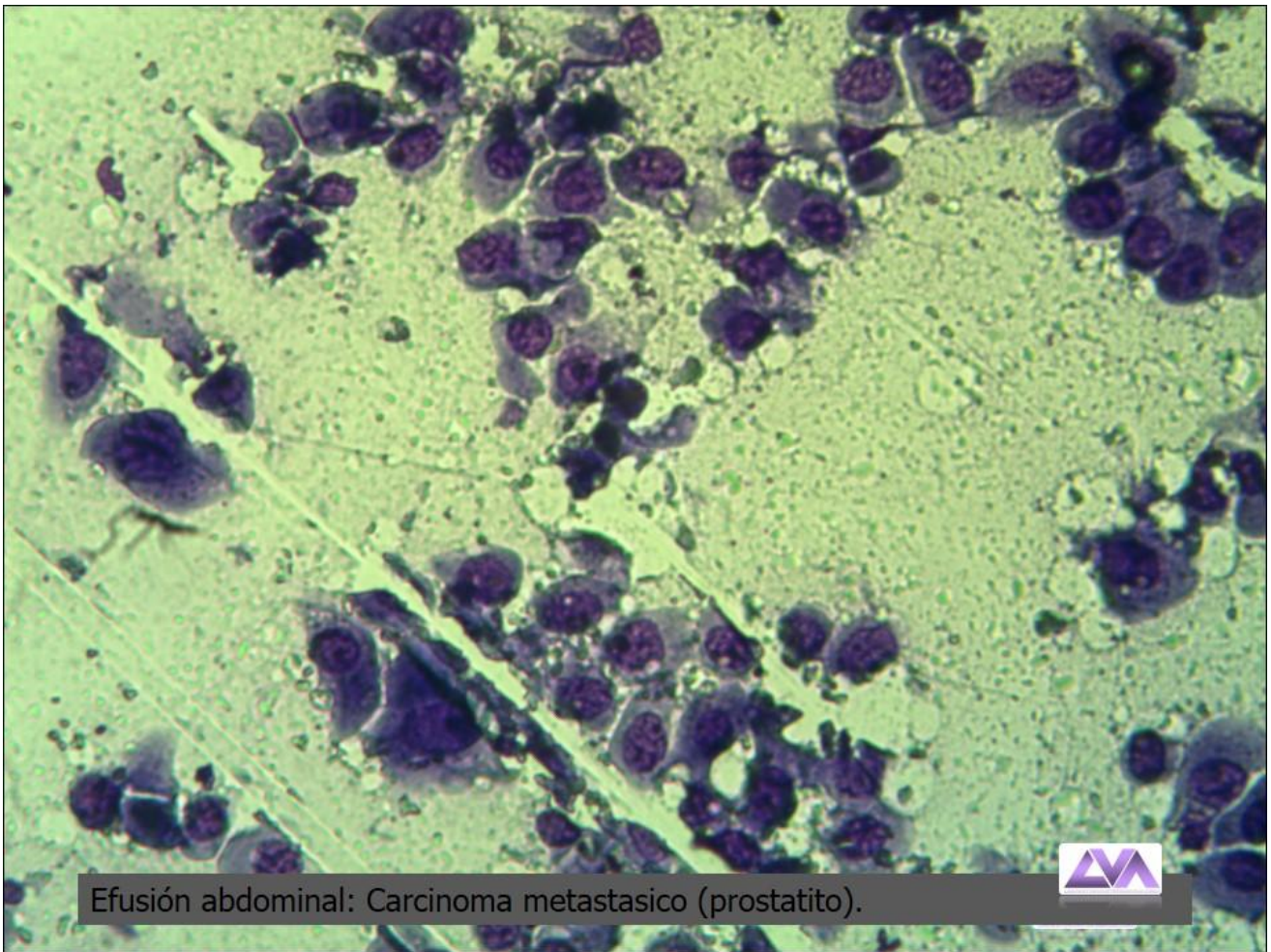
ATLAS DE CITOLOGIA DE EFUSIONES



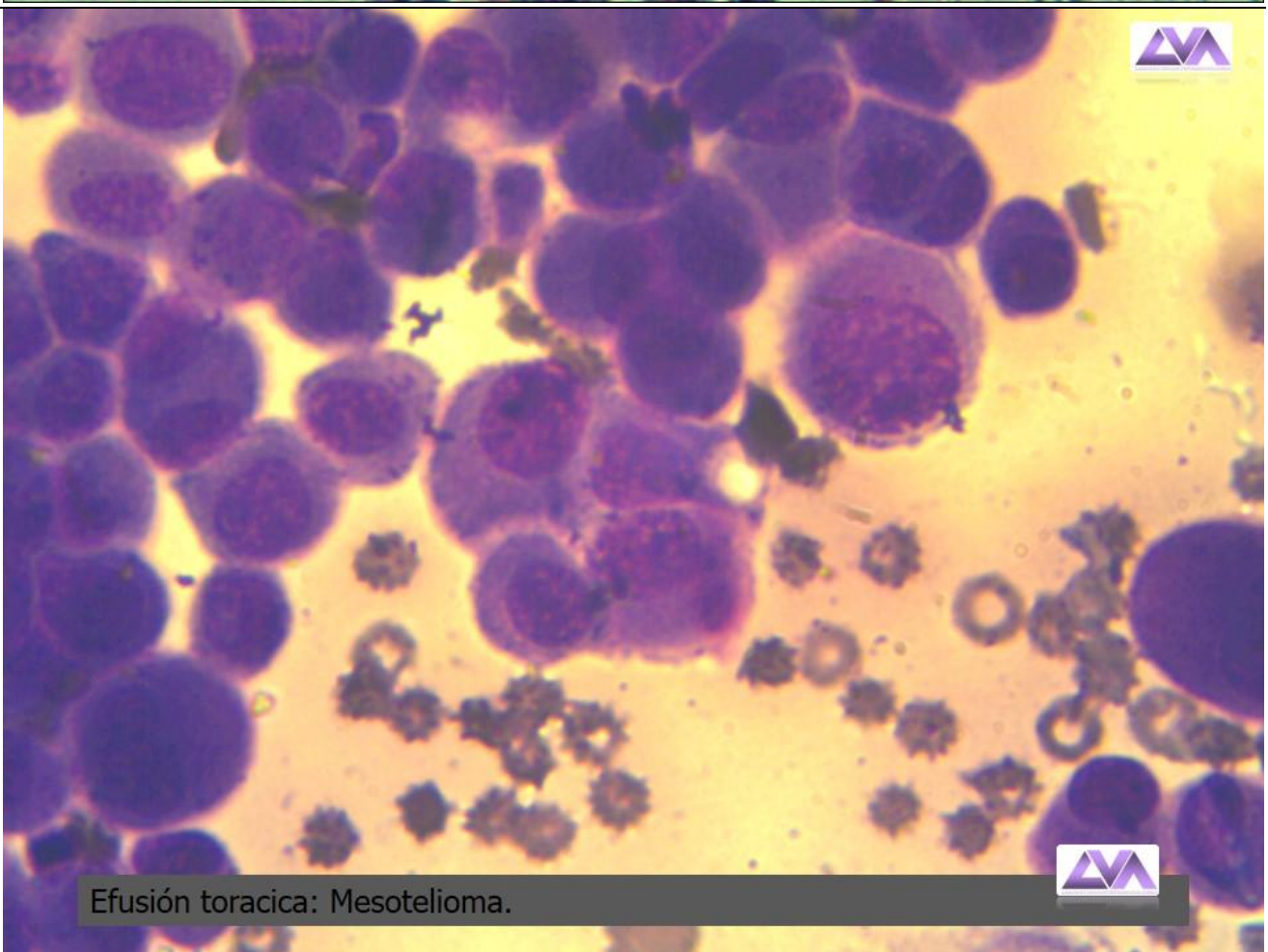
Efusión torácica: Carcinoma broncogenico



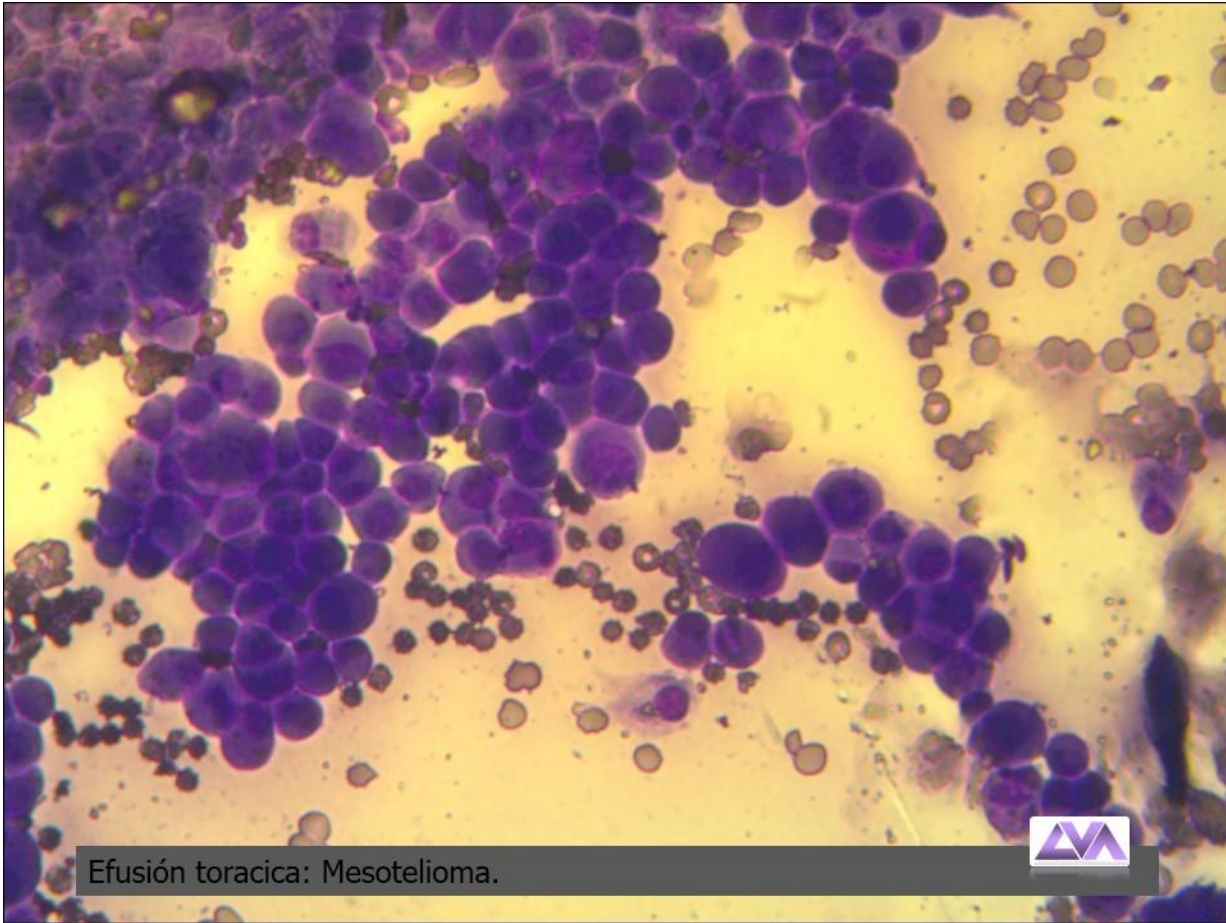
Efusión torácica: Carcinoma broncogenico



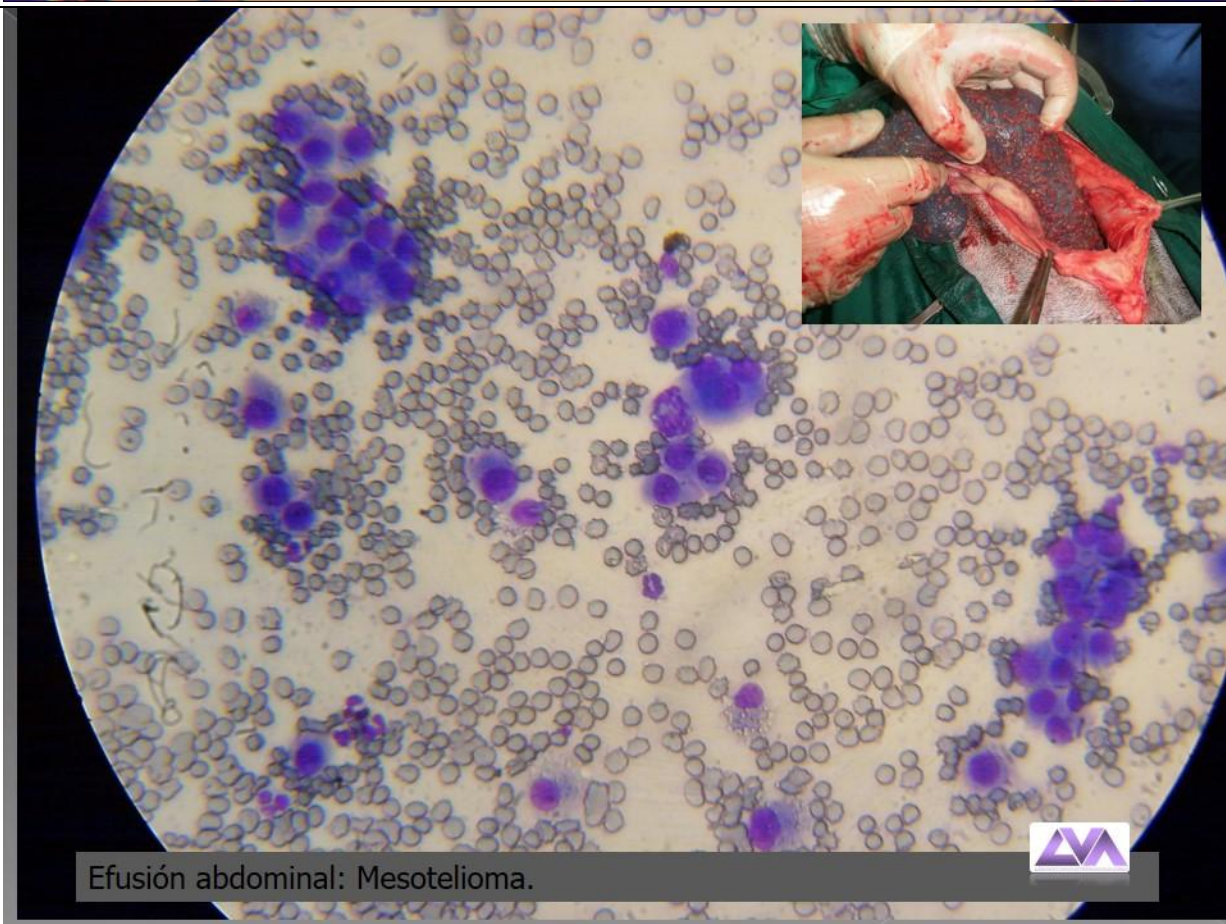
Efusión abdominal: Carcinoma metastasico (prostatito).



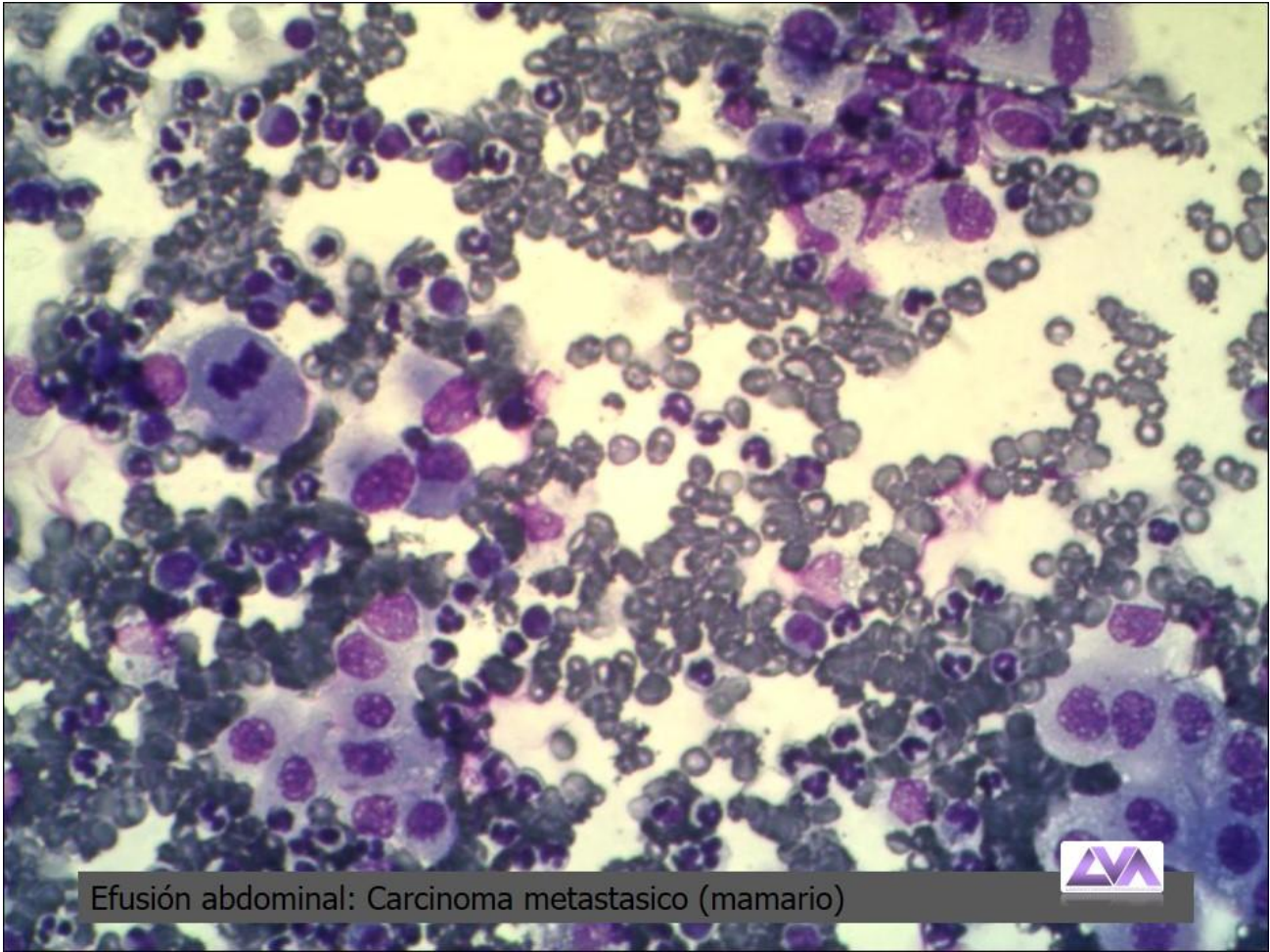
Efusión toracica: Mesotelioma.



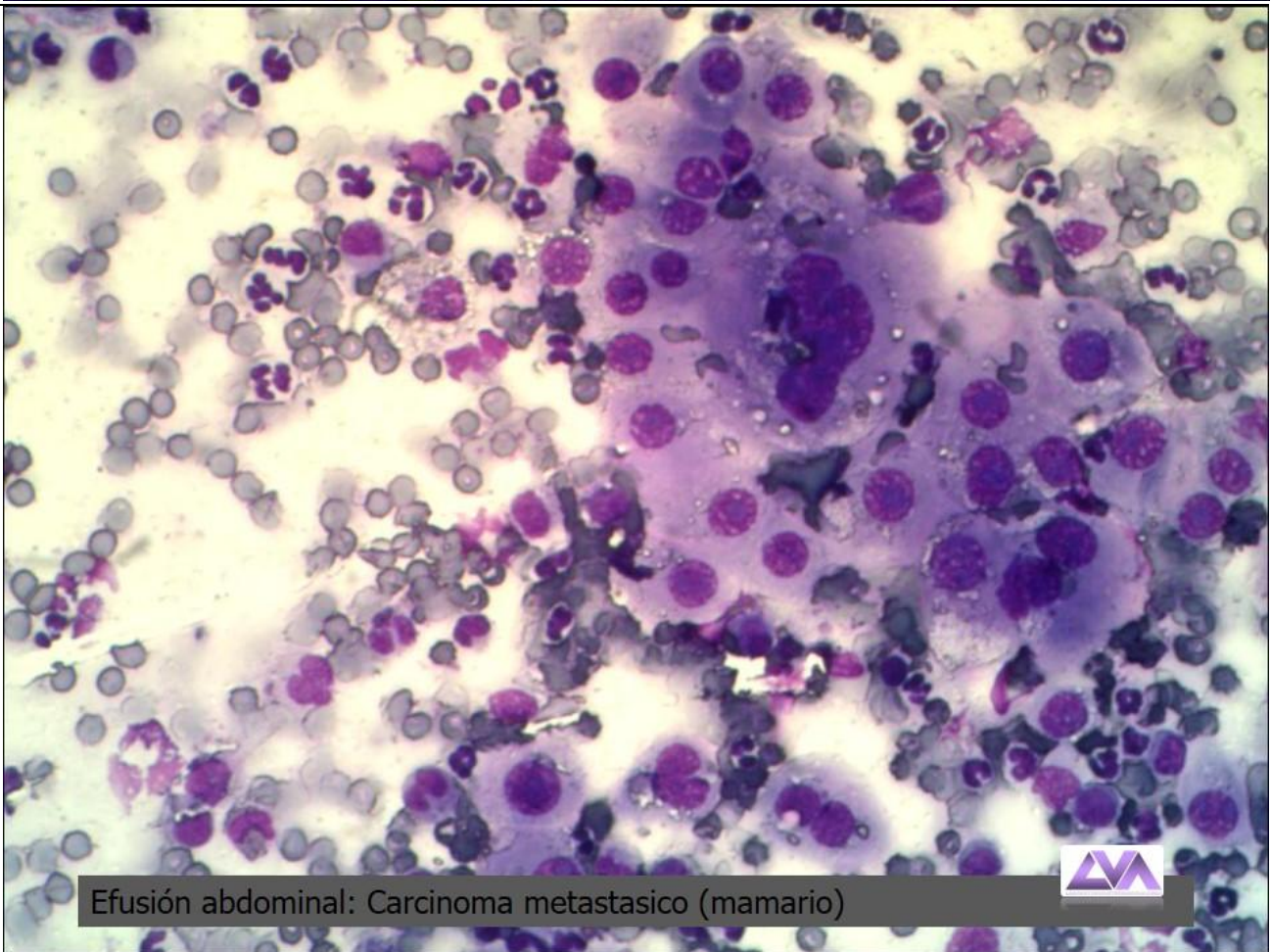
Efusión torácica: Mesotelioma.



Efusión abdominal: Mesotelioma.

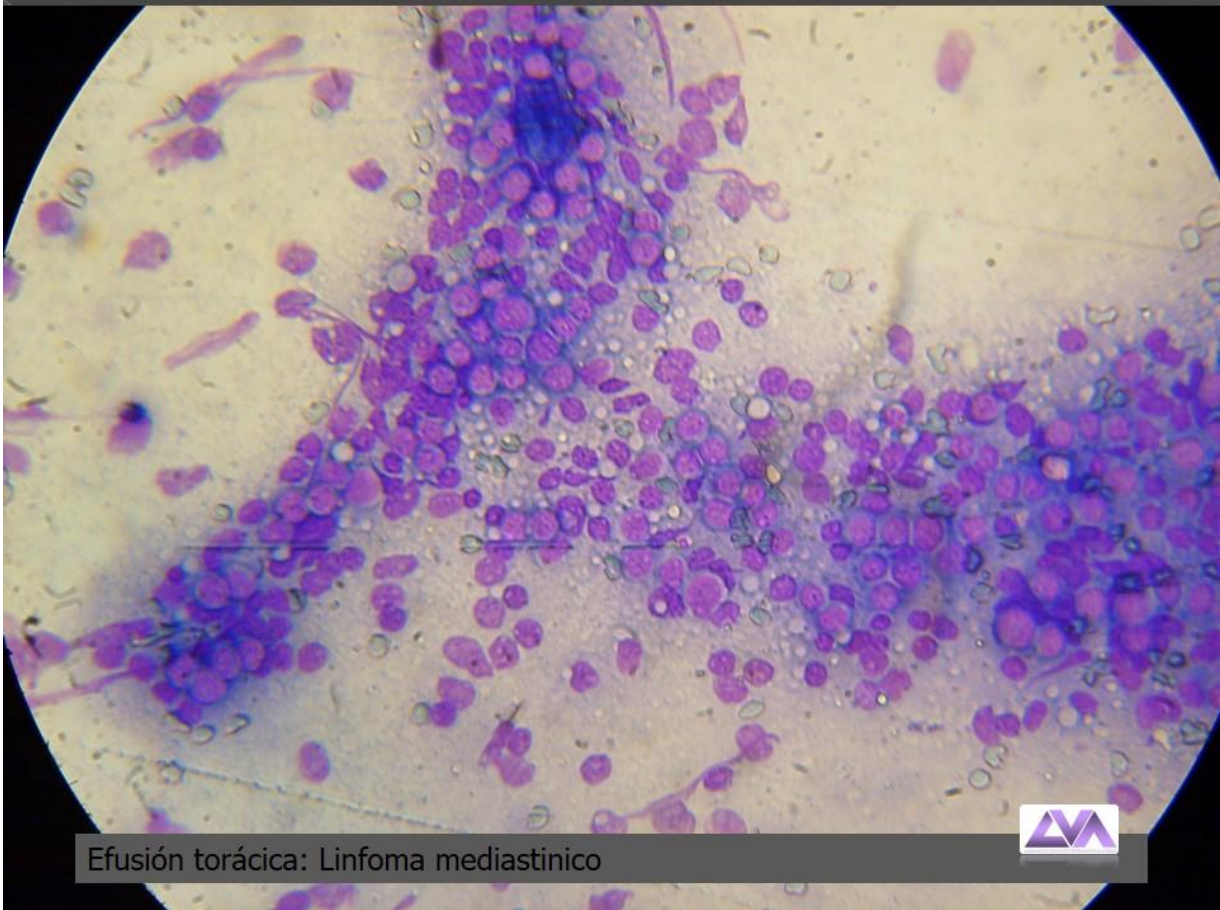

Efusión abdominal: Carcinoma metastasico (mamario)

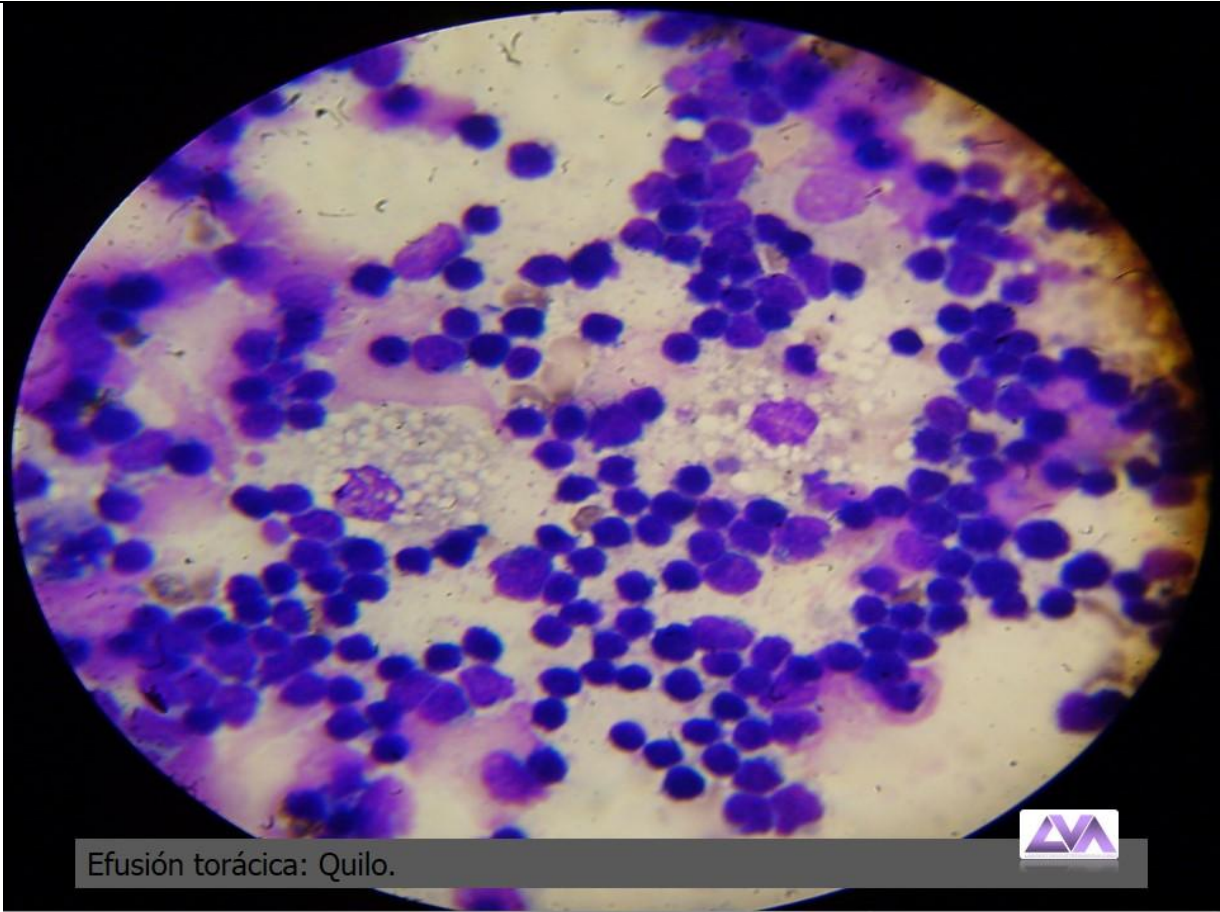


Efusión abdominal: Carcinoma metastasico (mamario)

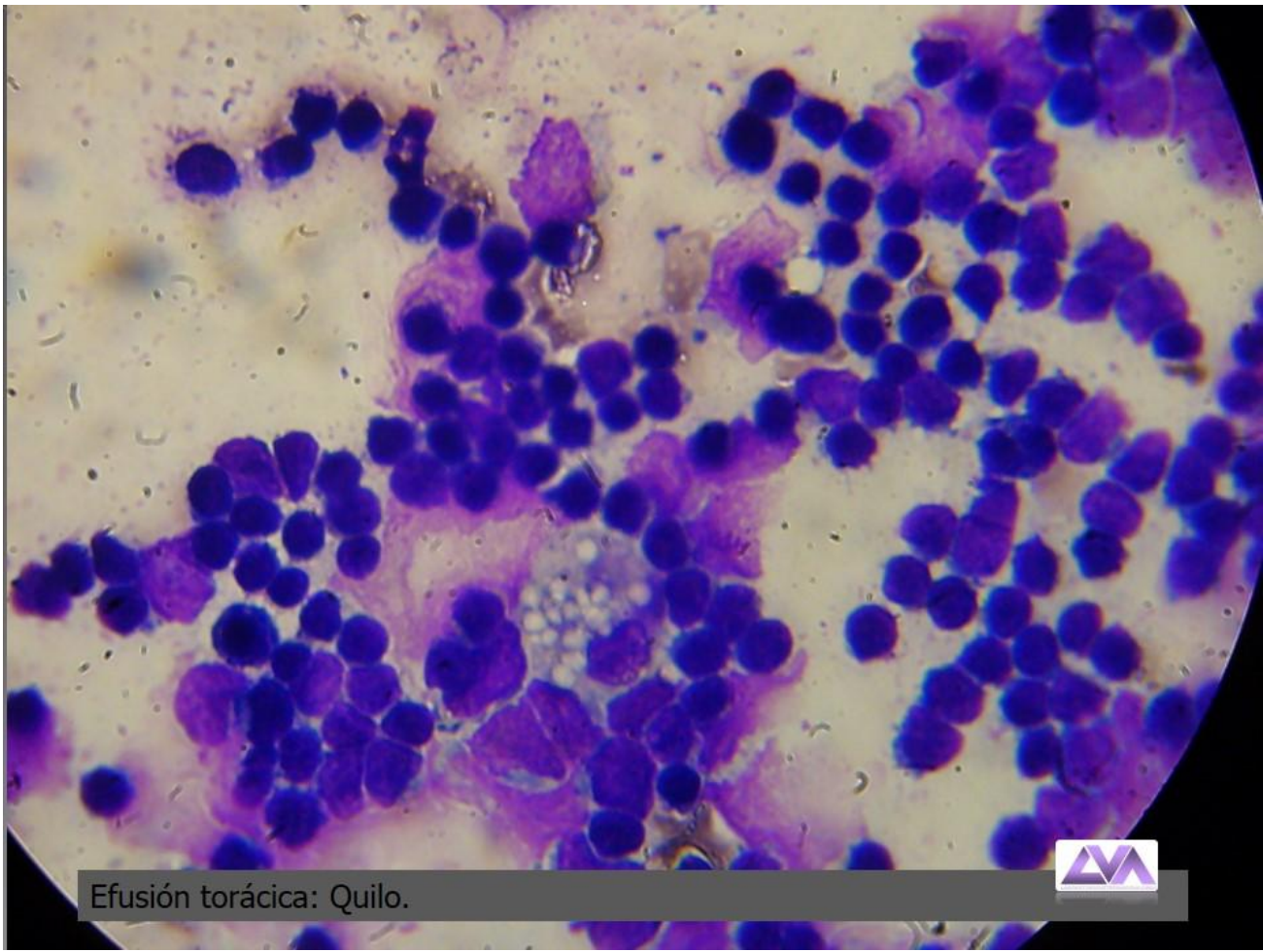




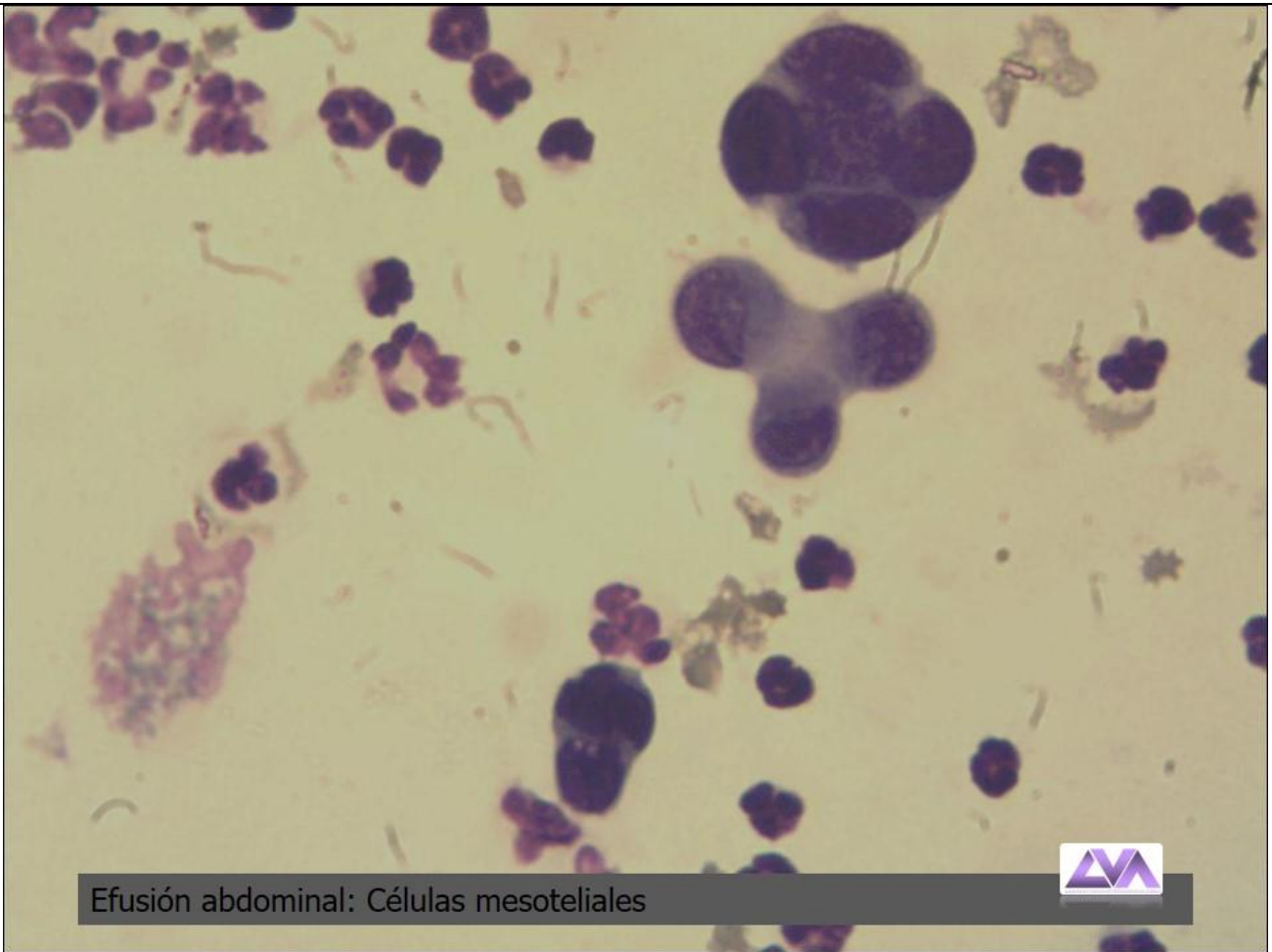
Efusión torácica: Linfoma mediastinico



Efusión torácica: Quilo.

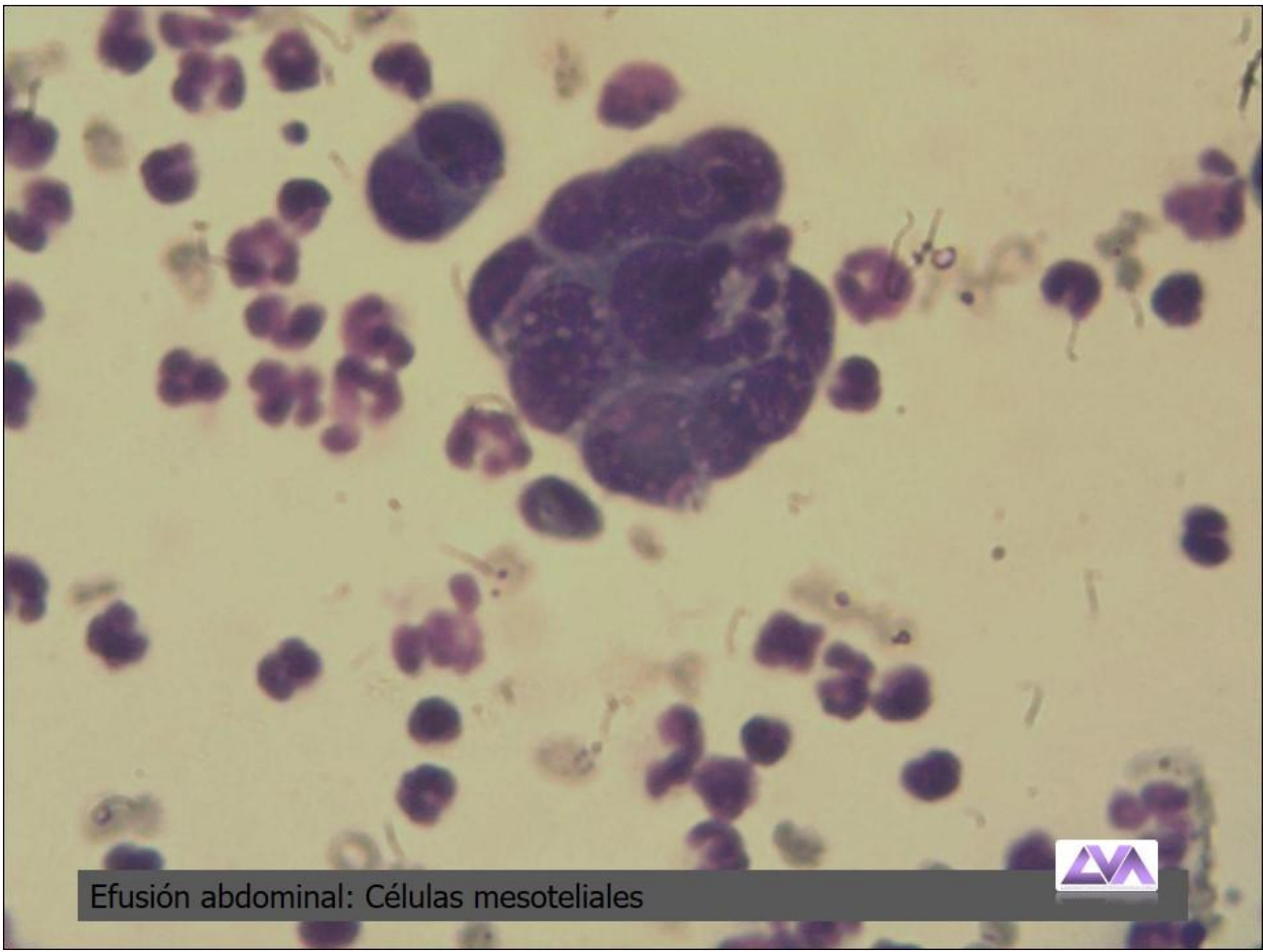


Efusión torácica: Quilo.

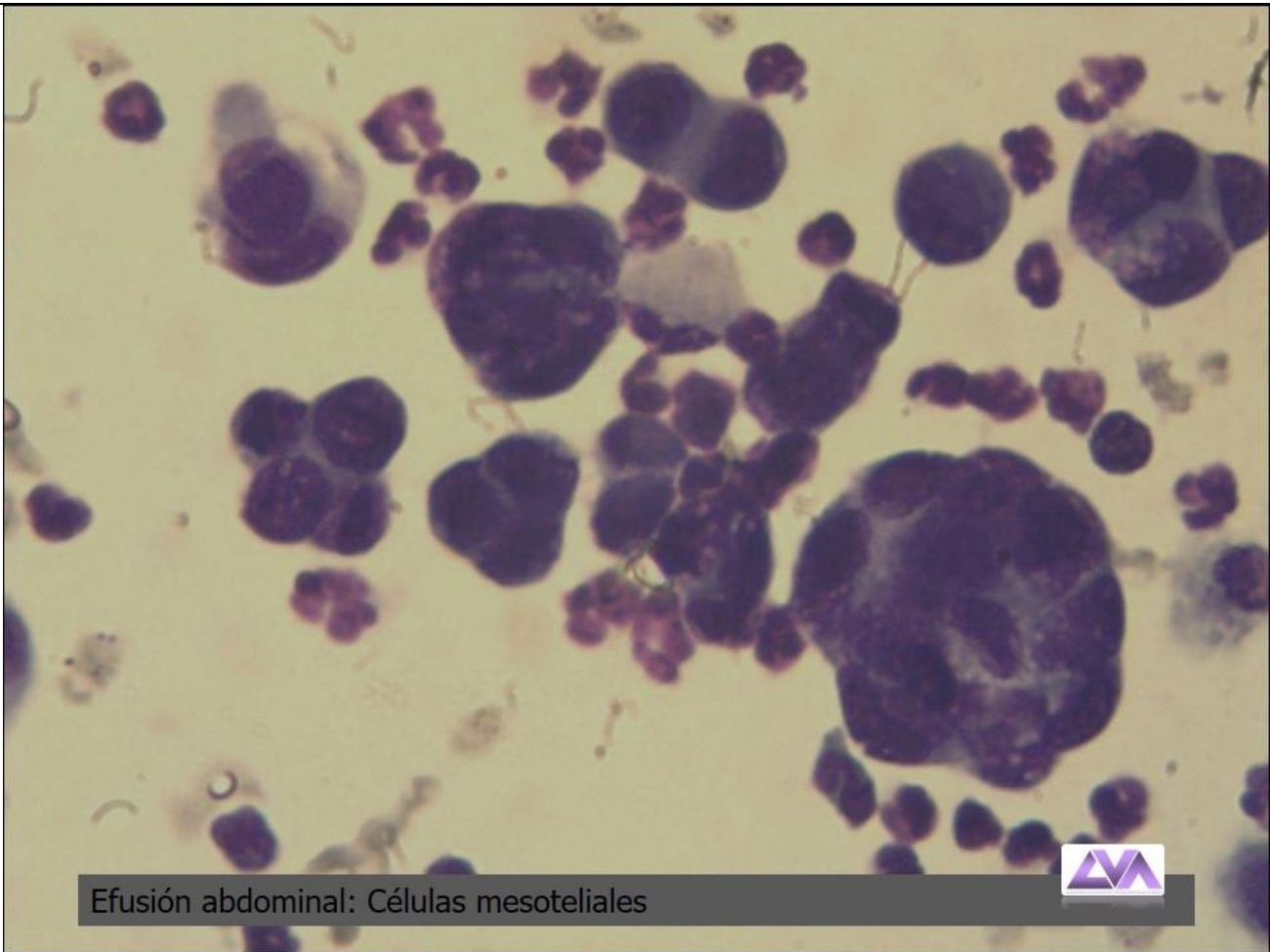


Efusión abdominal: Células mesoteliales



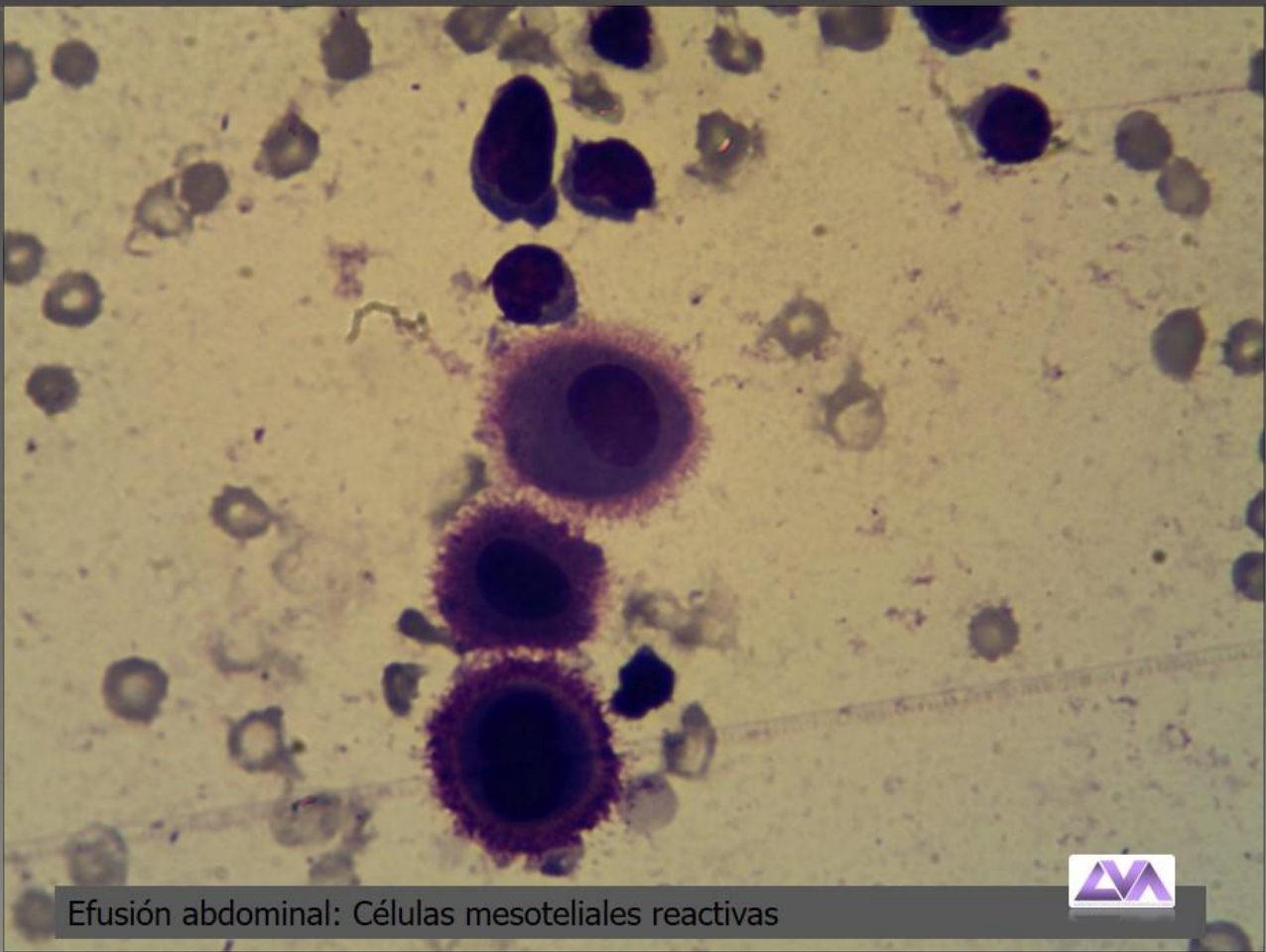


Efusión abdominal: Células mesoteliales



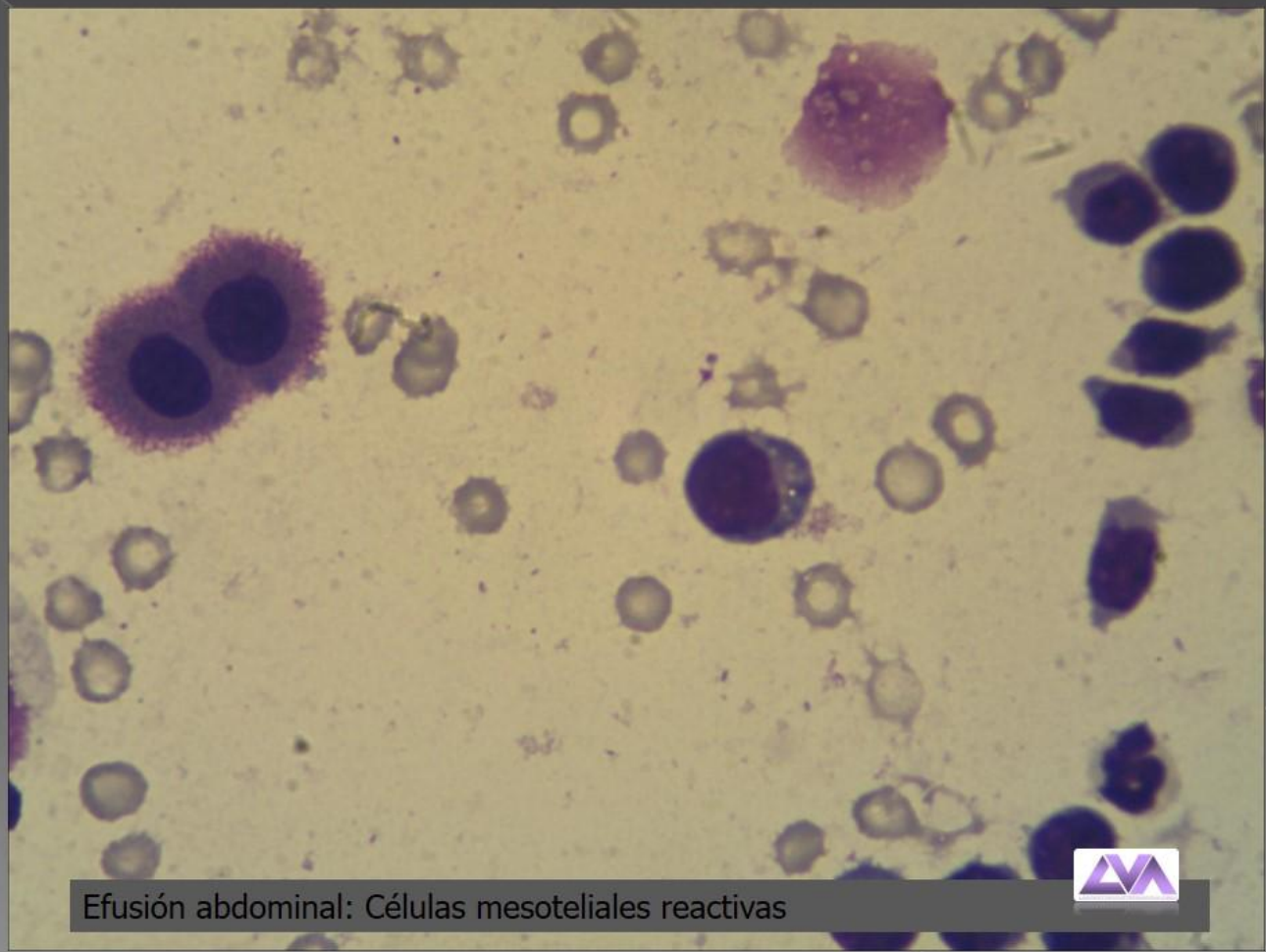
Efusión abdominal: Células mesoteliales





Efusión abdominal: Células mesoteliales reactivas





Efusión abdominal: Células mesoteliales reactivas

